

Title:

When breast cancer spreads below the belt — A case of rectal metastasis from invasive lobular carcinoma

Authors:

Julieta Puente-Monserrat, Leticia Pérez-Santiago, Liria Terrádez-Mas, Vicente Pla-Martí, David Casado-Rodrigo, José Martín-Arévalo, David Moro-Valdezate, Stephanie Anne García-Botello

DOI: 10.17235/reed.2025.11378/2025

Link: [PubMed \(Epub ahead of print\)](#)

Please cite this article as:

Puente-Monserrat Julieta, Pérez-Santiago Leticia, Terrádez-Mas Liria, Pla-Martí Vicente, Casado-Rodrigo David, Martín-Arévalo José, Moro-Valdezate David, García-Botello Stephanie Anne. When breast cancer spreads below the belt — A case of rectal metastasis from invasive lobular carcinoma. Rev Esp Enferm Dig 2025. doi: 10.17235/reed.2025.11378/2025.

This is a PDF file of an unedited manuscript that has been accepted for publication. As a service to our customers we are providing this early version of the manuscript. The manuscript will undergo copyediting, typesetting, and review of the resulting proof before it is published in its final form. Please note that during the production process errors may be discovered which could affect the content, and all legal disclaimers that apply to the journal pertain.

When breast cancer spreads below the belt — A case of rectal metastasis from invasive lobular carcinoma

Julieta Puente-Monserrat¹, Leticia Pérez-Santiago¹, Liria Terrádez-Mas², Vicente Pla-Martí^{1,3}, David Casado-Rodrigo¹, José Martín-Arévalo^{1,3}, David Moro-Valdezate^{1,3}, Stephanie García-Botello^{1,2}

1. Colorectal Surgery Unit, Department of General and Digestive Surgery, Hospital Clínico Universitario, INCLIVA Biomedical Research Institute. Valencia, Spain.
2. Department of Pathological Anatomy, Hospital Clínico Universitario, Valencia, Spain.
3. Department of Surgery, University of Valencia, Spain.

Corresponding author:

Leticia Pérez Santiago

Email: letperezsantiago@gmail.com

Address: Avenida Blasco Ibáñez Nº 17 46021. Valencia. España

ORCID:

- Julieta Puente Monserrat: 0009-0004-1369-191X
- Leticia Pérez Santiago: 0000-0002-3090-8330
- Vicente Pla-Martí: 0000-0001-7644-8416
- David Casado-Rodrigo: 0000-0003-0869-7992
- José Martín-Arévalo: 0000-0001-5337-9577
- David Moro-Valdezate: 0000-0003-0425-8677
- Stephanie García-Botello: 0000-0001-6921-4902

Keywords: Breast cancer. Gastrointestinal metastasis. Lobular carcinoma. Rectal metastasis.

Dear Editor,

We present the case of a 62-year-old woman diagnosed in 2014 with invasive luminal A lobular carcinoma (ILC) of the breast (T3N0M0). She underwent a modified radical mastectomy, followed by radiotherapy and five years of endocrine therapy with letrozole. In 2021, therapy

was discontinued due to musculoskeletal side effects. Seven years after diagnosis, the patient developed symptoms of partial bowel obstruction, along with a progressive rise in CA15.3 levels during oncological follow-up. Multiple diagnostic evaluations—including colonoscopies, enteric MRI, and PET scan—yielded normal results, initially suggesting inflammatory bowel disease.

In 2025, due to persistent symptoms, an abdominopelvic computed tomography (CT) was performed, which revealed concentric thickening of the rectal wall (Fig. 1A). Given to the continued tumour marker elevation and imaging findings, a rigid rectoscopy was carried out, revealing a 4-centimeter circumferential stenosis. Biopsies were obtained. Histopathological analysis confirmed metastatic breast carcinoma, with infiltration of the lamina propria (Fig. 1B) by cells expressing GATA3 (Fig. 1C) and TRPS1 (Fig. 1D)—breast-specific transcription factors—and loss of E-cadherin expression (Fig. 1E), consistent with ILC. Following histological confirmation of rectal metastasis, the patient initiated systemic chemotherapy with capecitabine.

Discussion:

ILC known for its potential to metastasize late and to uncommon sites, including the gastrointestinal tract. Benabdallah et al. reported a similar case of a patient presenting with chronic diarrhoea 11 years after an ILC diagnosis, ultimately identified as having colonic metastases on biopsy [1]. Posado-Domínguez et al. described a patient with a history of lobular breast carcinoma who presented with late gastric metastasis 12 years after the initial diagnosis [5]. In our case, the patient developed symptoms of partial bowel obstruction seven years post-diagnosis, and histological examination confirmed metastatic recurrence. While some GI metastases may remain asymptomatic [4], symptomatic presentations typically include obstruction, perforation, or gastrointestinal bleeding [3][4][5].

Gastrointestinal metastases from ILC, although rare, carry important diagnostic implications due to their diffuse growth pattern and tendency to mimic benign or primary gastrointestinal diseases. Recognition of this metastatic pattern is essential for timely diagnosis and management [1][3].

Conclusion

In patients with a history of breast cancer presenting with gastrointestinal symptoms, late metastatic disease should always be considered as part of the differential diagnosis.

References:

1. Benabdallah R, Bouzid Z, Bouzid T, et al. Late metastases: a rare cause of diarrhea. *Rev Esp Enferm Dig.* 2024. doi:10.17235/reed.2024.10399/2024.
2. Kioleoglou Z, Gaitanidis A, Vaiopoulos A, et al. Gastrointestinal metastases from lobular breast carcinoma: a literature review. *Cureus.* 2024;16(7):e65852.
3. Pla V, Aracil X, Lacy AM, et al. Metástasis de carcinoma ductal infiltrante de mama simulando un cáncer de colon obstructivo primario. *Cir Esp.* 2002;71(5):257-8.
4. Ng CE, Ooi LL, Ho LM, et al. Rectal metastasis from breast cancer: a rare entity. *Int J Surg Case Rep.* 2015;13:103-5.

5. Posado-Domínguez L, Figuero Pérez L, Corvo-Felix L, Díaz Sánchez P, Redondo-González JC, Pablo-Martín E, Rodríguez-Sánchez CA, Fonseca-Sánchez E. Late recurrence of lobular breast carcinoma presented as gastric metastasis. *Rev Esp Enferm Dig.* 2024 Aug;116(8):455-456. doi: 10.17235/reed.2023.9987/2023. PMID: 37882182.

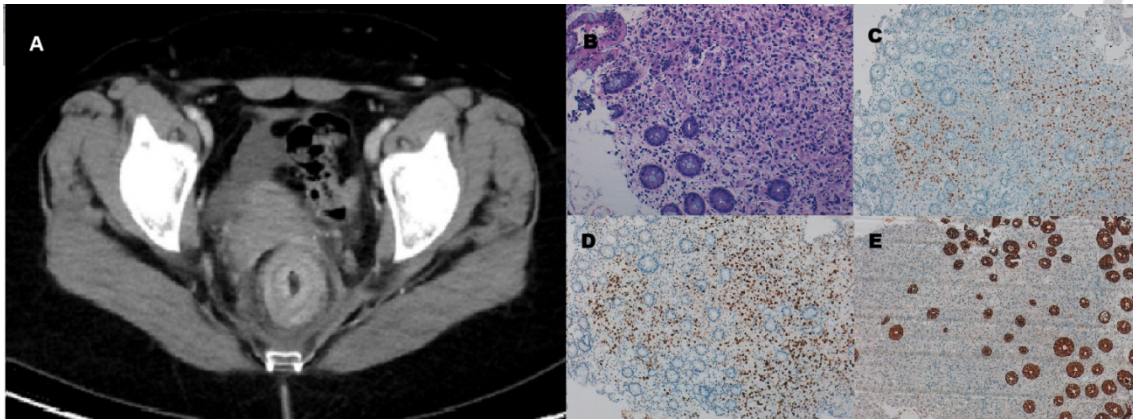


Figure 1: **A.** Abdominopelvic CT scan showing concentric thickening of the rectal wall. **B.** Hematoxylin and eosin stain: rectal mucosa on the left with preserved crypt architecture. On the right, the lamina propria is infiltrated by cells arranged in a dispersed and infiltrative pattern. **C. & D.** GATA3 and TRPS1: nuclear positivity for these markers, with absence of expression in colonic epithelium. **E.** E-cadherin: normal colonic crypts show strong positive staining (dark brown), while tumor cells completely lack expression.