

Accepted Article

Minimally invasive treatment of rectovesical fistula: A case report

Alba Manuel Vázquez, Francisco Javier Jiménez Miramón,
José Luis Ramos Rodríguez, José María Jover Navalón

DOI: [10.17235/reed.2016.4017/2015](https://doi.org/10.17235/reed.2016.4017/2015)

Link: [PDF](#)

Please cite this article as: Manuel Vázquez Alba, Jiménez Miramón Francisco Javier, Ramos Rodríguez José Luis, Jover Navalón José María. Minimally invasive treatment of rectovesical fistula: A case report. Rev Esp Enferm Dig 2016. doi: 10.17235/reed.2016.4017/2015.



This is a PDF file of an unedited manuscript that has been accepted for publication. As a service to our customers we are providing this early version of the manuscript. The manuscript will undergo copyediting, typesetting, and review of the resulting proof before it is published in its final form. Please note that during the production process errors may be discovered which could affect the content, and all legal disclaimers that apply to the journal pertain.

Minimally invasive treatment of rectovesical fistula: a case report

Alba Manuel Vázquez, Francisco Javier Jiménez-Miramón, José Luis Ramos-Rodríguez and José María Jover-Navalón

Department of General and Digestive Surgery. Hospital Universitario de Getafe. Getafe, Madrid. Spain

Correspondence: Alba Manuel Vázquez

e-mail: alba_manuel_vazquez@hotmail.com

Key words: Rectovesical fistula. Transanal endoscopic surgery. Minimally invasive surgery.

Dear Editor:

Management of rectovesical fistulas (RVF) poses a significant challenge as they affect quality of life and cause persistent urinary infections or even abdominal sepsis (1). We report our first case of transanal endoscopic surgical treatment of RVF with a successful outcome.

Clinical case

A 57-years-old man with laparoscopic radical prostatectomy by neoplasia. During postoperative period, he presents fecaluria and pneumaturia. With a diagnosis of RVF, we perform a laparoscopic colostomy.

Cystoscopy does not show extravasation to rectum. With clinical data and positive urine cultures, we perform barium enema, showing the presence of RVF (Fig. 1A). After discussion, a transanal endoscopic surgical repair by transanal endoscopic operation is planned. We visualize the orifice of the fistula at anterior rectal wall (Fig. 1B) and perform a dissection of the fistula tract, followed by a resection, and we close by suturing (Fig. 1 C and D).

Three months after surgery the urine culture is negative and the barium enema does not show fistula tract (Fig. 1 E and F). For these reasons we perform a stoma closure, with no complications.

Discussion

Management of RVF is complex. The rate of spontaneous closure after urinary and/or fecal diversion has been reported to be 14 to 46.5% (2), especially in small fistulas without history of radiation (3). This implies that a definitive surgical treatment is necessary in the majority of the patients.

A variety of surgical procedures has been described: transperineal, transsphincteric, conventional transanal or transabdominal approaches, implying that there is no consensus about a gold standard.

The overall success rate of surgical management of RVF is high, over 90%, regardless of a history of radiation or the procedure type, being debridement of the fistula tract to healthy tissue essential for the successful outcome (1). Traditional surgery is technically demanding, needs extensive dissections and jeopardizes continence (4,5).

The development of transanal endoscopic surgery, that was originally described to perform resection of early rectal tumors, and the increasing interest in minimally invasive surgery have led to use this technique for RVF repair (6-8). Its key points are the dissection of mucosa until the proper muscle is completely exposed, the resection of the mucosal layer and fistula tract and the closure of the defect by suturing (8). The most important advantages it provides are excellent the visualization of the surgical field and surgery without incision in healthy tissue. It is fundamental that this approach is carried out by skilled colorectal surgeons.

Recently, some favorable results by endoscopic treatments (cyano-acrylate injection or the scope clip) have been reported (9,10).

Therefore, several procedures have been described for the treatment of RVF. The application of transanal endoscopic surgery to RVF is safe, feasible and useful, adding the advantages of a minimally invasive surgery. In our experience, we consider that it is necessary to confirm healing before reversing stoma with barium enema to guarantee a successful outcome.

References

1. Nfonsam VN, Mateka JJ, Prather AD, et al. Short-term outcomes of the surgical management of acquired rectourethral fistulas: Does technique matter? *Res Rep Urol* 2013;5:47-51.
2. Choi JH, Jeon BG, Choi SG, et al. Rectourethral fistula: Systematic review of and experiences with various surgical treatments methods. *Ann Coloproctol* 2014;30:35-41. DOI:

10.3393/ac.2014.30.1.35

3. Hechenbleikner EM, Buckley JC, Wick EC. Acquired rectourethral fistulas in adults: A systematic review of surgical repair techniques and outcomes. *Dis Colon Rectum* 2013;56:374-83. DOI: 10.1097/DCR.0b013e318274dc87
4. Razi A, Yahyazadeh SR, Gilani MA, et al. Transanal repair of rectourethral and rectovaginal fistulas. *Urol J* 2008;5:111-4.
5. Bochove-Overgaauw DM, Beerlage HP, Bosscha K, et al. Transanal endoscopic microsurgery for correction of rectourethral fistulae. *J Endourol* 2006;20:1087-90. DOI: 10.1089/end.2006.20.1087
6. Wilbert DM, Buess G, Bichler KH. Combined endoscopic closure of rectourethral fistula. *J Urol* 1996;155:256-258. DOI: 10.1016/S0022-5347(01)66612-6
7. Andrews EJ, Royce P, Farmer KC. Transanal endoscopic microsurgery repair of rectourethral fistula after high-intensity focused ultrasound ablation of prostate cancer. *Colorectal Dis* 2011;13:342-3. DOI: 10.1111/j.1463-1318.2010.02224.x
8. Kanehira E, Tanida T, Kamei A, et al. Transanal endoscopic microsurgery for surgical repair of rectovesical fistula following radical prostatectomy. *Surg Endosc* 2015;29:851-5. DOI: 10.1007/s00464-014-3737-x
9. Mangiavillano B, Pisani A, Viaggi P, et al. Endoscopic sealing of a rectovesical fistula with a combination of an over the scope clip and cyano-acrylate injection. *J Gastrointest Oncol* 2010;1:122-4.
10. Mori H, Kobara H, Fujihara S, et al. Rectal perforations and fistulae secondary to a glycerin enema: Closure by over-the-scope-clip. *World J Gastroenterol* 2012;28:3177-80. DOI: 10.3748/wjg.v18.i24.3177

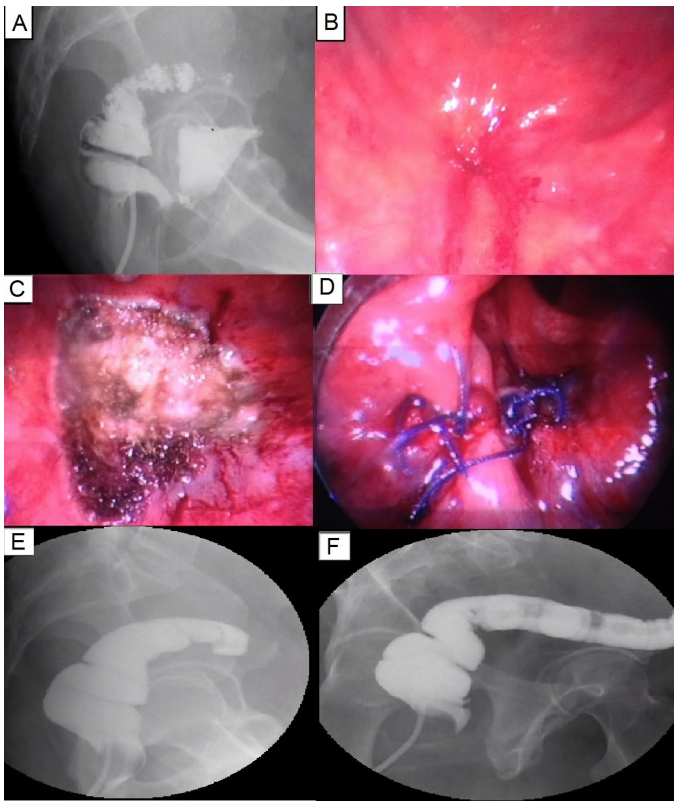


Fig. 1. A. Barium enema: rectovesical fistula. B. Fistula orifice at anterior rectal wall. C. After resection of the fistula by transanal endoscopic operation. D. Closure by suturing. E and F. Barium enema without rectovesical fistula.