

Title:

Clinical-endoscopic relevance of incidental colorectal lesions detected by PET-CT

Authors:

Carmen Garrido Durán, María Antonia Payeras Capó, Carmen García Caparrós, Marta Giménez García, Jaime Daumal Domenech

DOI: 10.17235/reed.2018.4719/2016

Link: [PubMed \(Epub ahead of print\)](#)

Please cite this article as:

Garrido Durán Carmen, Payeras Capó María Antonia, García Caparrós Carmen, Giménez García Marta, Daumal Domenech Jaime. Clinical-endoscopic relevance of incidental colorectal lesions detected by PET-CT. Rev Esp Enferm Dig 2018. doi: 10.17235/reed.2018.4719/2016.

Enero 2017 • Volumen 109 • Número 1 • Páginas 1-86

Revista Española de Enfermedades Digestivas
THE SPANISH JOURNAL OF GASTROENTEROLOGY

Acceso al texto completo en: www.reed.es o www.sped.es

Factor de impacto 2016: JCR: 1.455-1248
SCR: 0.34-1026

ORGANO OFICIAL DE:
SOCIEDAD ESPAÑOLA DE PATOLOGÍA DIGESTIVA, SOCIEDAD ESPAÑOLA DE ENDOSCOPIA DIGESTIVA Y ASOCIACIÓN ESPAÑOLA DE ECOGRAFÍA DIGESTIVA

SEPOD

Editorial Colonic diverticular bleeding. Have we identified the risk factors for massive bleeding yet? J. W. Berman Valencia	Lesión de Bowdler: diagnóstico por gastroscopia R. Barrio Iglesias, M. N. Barrio Irujo, M. Paz Novas y J. E. Domínguez Muñoz	65
Trabajos Originales Risk factors for severity and recurrence of colonic diverticular bleeding N. Anzueto, P. Calvo, A. Arduas, M. Escobar and M. Guzmán	Notas Clínicas Celiac crisis in adults: a case report and review of the literature focusing in the presentation of subacute-onset M. de Alaveda-Nemón, V. L. Barrio-Cabral and S. L. Lopera	67
Microsporidian and inflammatory bowel disease: the other Diogenes J. Barrio, A. Aguiló, V. López-Castejón, J. Cuervo, M. Acuña-Barca, M. Hernández-Serra, C. García, M. de la Cruz, D. Barrio and A. López-Castejón	Herangopercutaneous peritoneal lysis localization infrequent in benign mesothelioma I. Alvaró Abad, J. M. García-Cerdillo, L. Aguirre-Duñabeitia, A. M. Quintana-Rivero y A. Colla-Morales	69
Influence of sustained 48-hr response on the regression of fibrosis and portal hypertension in cirrhotic HCV patients treated with antiviral therapy A. Barrio, J. Calvo, M. J. López-Alcalá, I. López, M. T. Ariza, A. Galván, F. Castiella, E. Fabrega and J. Crespo	Hemólisis por eritropoiesis suprarrenal C. Pérez-Carpas, A. Escobedo-Sánchez, M. A. Paredes-Capó, J. Arangul-Arribas y C. García-Delgado	70
Malnutrition risk questionnaire combined with body composition measurement in malnutrition screening in inflammatory bowel disease A. A. Cortés, A. Muñoz, Z. Pilo, I. Pall and P. Muñoz	Endoscopic removal of intubated large varicose gastric: a case report M. Oquendo and J. Sainza-Munizaga	73
A survey-based analysis of endoscopic quality indicators compliance among Spanish endoscopists I. Fernández-Cruz, F. Argüelles, P. Alonso, J. Salas and S. Soriano	Mesenteric schwannoma: an unusual cause of abdominal mass A. Tapia-Palacio, M. R. Ramos-Vázquez, J. C. Cordero-Ramos, J. Cordero-Lafont and L. Carillo-Pérez	76
Revisión Endoscopic resection of colorectal polyps in patients on antiplatelet therapy: an evidence-based guideline for clinicians G. Piana, M. Sostero-Salín, C. Salinas, F. Day and M. J. Cuatrecasas	Cartas al Editor Necrotizing enterocolitis: not just a tumor plus tubulosis M. de Barrio, M. J. Barrio-Fernández and M. N. Barrio	79
Indicadores en Patología Digestiva Sequelae of the upper esophageal sphincter: a case of infundibular diverticulum J. Barrio, P. Alvaró, M. J. Barrio y J. C. García-Pérez	Presentación insular de adenocarcinoma gástrico: diagnóstico asociado a consumo de Bismuto, patología infrecuente y poco conocida Y. Pineda-Vega, D. M. Acosta y L. A. Alvaró	80
Neurosis orgánica intestinal A. F. Barrio-Muñoz y R. Barrio-Zalaga	Peroral endoscopic myotomy for an achalasia patient with multiple esophageal diverticula Y. Sun, H. Zhu and D. Liu	81
Tumores de Wilms a cinco años de diagnóstico C. Ochoa-Sandoval, C. C. Hernández-Segura, J. Pineda-Rodríguez y A. N. González-Fernández	Análisis de endoscopia intestinal, endoscopia infradiaphragmática y el diagnóstico diferencial de adenocarcinoma gástrico C. Sánchez-Jiménez, I. Guevara-Nieto y J. A. Acosta-Paredes	81
Endoscopic removal of leiomyomas in a schistosomiasis patient J. L. Barrio-Hernández, M. E. Torres-Castro and M. Torres-Rodríguez	Perforación múltiple de divertículos de intestino delgado en paciente con síndrome de Ulceras Duodenales R. Fernández-Cruz, A. Barrio-Cerdillo y E. Palencia-López	83
All that glitters is not gold: A different cause for an "obscure colitis" A. Pineda, M. Sainza, J. Villaverde and S. Navas	Atrofia antral como manifestación paraneoplásica de un adenocarcinoma gástrico J. Barrio-Cerdillo, F. Fernández-Serrano y J. de la Fuente-Aguado	83
	Revisores 2016	85

ARAN

www.reed.es

This is a PDF file of an unedited manuscript that has been accepted for publication. As a service to our customers we are providing this early version of the manuscript. The manuscript will undergo copyediting, typesetting, and review of the resulting proof before it is published in its final form. Please note that during the production process errors may be discovered which could affect the content, and all legal disclaimers that apply to the journal pertain.

OR 4719 inglés

Clinical-endoscopic relevance of incidental colorectal lesions detected by PET-CT

Carmen Garrido-Durán¹, Maria Antonia Payeras-Capó¹, Carmen García-Caparrós¹,
Marta Giménez-García² and Jaume Dalmau-Domenech²

Department of ¹Digestive Diseases and ²Nuclear Medicine. Hospital Universitario Son Espases. Palma de Mallorca, Spain

Received: 16/11/2017

Accepted: 13/01/2018

Correspondence: Maria Antonia Payeras-Capó. Department of Digestive Diseases. Hospital Universitario Son Espases. Carr. de Valldemossa, 79. 07120 Palma de Mallorca, Islas Baleares. Spain
e-mail: marian.payeras@gmail.com

ABSTRACT

Aim: to determine the proportion of incidental colon lesions detected by PET-CT and their correlation with the endoscopic and histological findings. In addition, to determine the maximum standardized uptake value (SUV_{max}) that can discriminate between benign and malignant lesions in our series of cases.

Methods: this was a retrospective study of 3,000 patients evaluated by PET-CT for staging or response to treatment of primary neoplasms, between 2011 and 2015. Patients with incidental uptake in the colon were included in the study. Exclusion criteria included an incomplete, poorly prepared or abandoned colonoscopy, inflammatory bowel disease and treatment with metformin.

Results: the study cohort comprised 71 patients evaluated by PET-CT and subsequently analyzed by endoscopy; 69% were male with a mean age of 65.77 ± 11.2. The rate of incidental colon lesions found by PET-CT was 1.73%, with 52 incidental colonic uptakes reported in 50 patients. The location of the uptake was the rectum (19.23%), sigmoid

colon (34.62%), descending colon (13.46%), transverse colon (1.9%), ascending colon (19.23%), cecum (9.62%) and ileocolic anastomosis (1.92%). Thirty-five pathological colonoscopies (71.15%) were identified: the findings included five neoplasms (13.51%), two inflammatory lesions (5.4%) and 30 adenomatous polyps (81.1%). Significant differences were found between neoplastic SUV_{max} (11.7 g/ml; p = 0.03) and polyps (9.26 g/ml; p = 0.04) in relation to inflammatory lesions and normal endoscopies (6.05 g/ml). There were no differences in terms of the size of the polyps, nor the presence or absence of high grade dysplasia (p = 0.12 and 0.33). Both PET-CT and endoscopy proved consistent for locating lesions (k 0.90; CI 95% 0.86-0.93).

Conclusion: there is a good correlation between the findings identified by PET-CT and the endoscopic study. In our study, a SUV_{max} > 11 g/ml suggests a malignant pathology, which aids the prioritization of an endoscopic study.

Key words: Positron emission tomography/computed tomography scan. Colorectal cancer. Incidental colorectal lesions. SUV_{max}. Colonoscopy.

INTRODUCTION

Positron emission tomography (PET) is based on the capture of a radioactive analogue of glucose ¹⁸F-2-fluoro-2-deoxyglucose (¹⁸F-FDG) by metabolically active cells. The technique is mainly used to determine staging and monitor neoplasms. The combination of this procedure with computed tomography (CT) scanning improves the detection of metabolically active foci (1,2).

The increasing use of PET-CT for the assessment of oncologic patients has led to an increasing number of incidental uptakes detected in the colon (2,3). These unexpected uptakes are often unspecific but could be indicative of inflammatory, premalignant or malignant lesions (4). Low intensity uptake frequently tends to be diffuse or lineal, which corresponds to the physiological activity within the large intestine. However, with more focal images of a higher intensity, it is more difficult to differentiate between a malignant transformation and a normal variant, as there is a high rate of false negatives and positives (1,4,5).

The use of PET-CT for the differentiation of malignant and benign pulmonary nodules is well established. However, its ability to distinguish between malignant and benign pathology is less apparent with regard to colon assessment (1). Based on this, the current recommendation is that colonoscopy procedures should be performed in all cases of incidental uptakes in the large intestine by PET-CT (6,7). Nevertheless, due to the fact that not all findings are related to pathological conditions and that unnecessary investigations could lead to a delay in the onset of treatment of primary illness, the choice of an appropriate evaluation diagnostic tool is often challenging. Therefore, a predictive risk factor for malignancy such as the maximum standardized uptake value (SUV_{max}), which defines the intensity of uptake, could be useful to determine the urgency of colonoscopy procedures (8).

This study aimed to investigate the proportion of incidental PET-CT uptake in the colon, evaluate their correlation with endoscopy and histology and determine the value of SUV_{max} that discriminates between benign and malignant lesions.

MATERIALS AND METHODS

This was a retrospective study to identify colonic uptake in 3,000 patients who underwent PET-CT between December 2011 and February 2015. Endoscopic and histological reports were reviewed whenever relevant and PET-CT findings were correlated with endoscopic and histological findings. Patients with a prior history of colorectal cancer were not excluded from the analysis. It is important to note that patients who had not undergone subsequent endoscopies or cases with incomplete or poorly prepared procedures were excluded. Patients with a history of inflammatory bowel disease or actively undergoing treatment with metformin at the time of PET-CT were also excluded. This is due to the fact that metformin leads to an intense increase of diffuse images of ^{18}F -FDG in the colon and, to a lesser extent, in the small intestine.

This limits the capacity of PET-CT diagnosis and possibly masks the detection of a neoplasm (9). Incidental uptake was defined as the focal accumulation of ^{18}F -FDG in patients that underwent a pathological study that was not related to the colon or in areas incompatible with the previously known pathology. The intensity of uptake was measured according to the value of SUV_{max} . All patients signed a written informed

consent for all diagnostic and therapeutic procedures.

Imaging technique

Images were taken with a GE ST70 tomograph, in strict accordance with the standard operating protocol. A body scan was performed from lower orbit to third proximal of the femur after intravenous administration of 6-10 mCi of ^{18}F -FDG. When areas of interest in the intestine with an unclear origin or elevated intensity were identified, a new “delayed” image was obtained at 90-180 minutes of 3 min/bed. When the original PET image identified a focal uptake which corresponded to the CT image, a repeat “delayed” procedure was deemed unnecessary.

Correlation with colonoscopy

Data related to subsequent colonoscopies was collected from the clinical history of all patients with identified regions of interest from the PET-CT study. Pathological reports were correlated with incidental uptake during PET-CT. Histological reports of a biopsy or polypectomy were obtained and the final diagnosis was reached according to the endoscopic findings and the histology of the lesion. Each region captured with ^{18}F -FDG with a subsequent negative colonoscopy was considered as physiological absorption.

Pathology

Histological analysis of a lesion obtained after colonoscopy was considered to be malignant when the following were identified: carcinomas, invasive adenomas, metastatic disease, primary malignancies and myeloproliferative processes infiltrating colonic mucosa. Hyperplastic polyps and adenomatous polyps (tubulous, villous and tubulovillous) were considered as non-malignant.

Statistical analysis

The statistical analysis was performed using the G-Stat version 2.0 and Epidat version 4.1 software. A descriptive analysis was performed to describe the characteristics of incidental uptake. Consistency was measured using the kappa (κ) coefficient with an established confidence interval (CI) of 95%. The t-test was used for the evaluation of

SUV_{max} to detect a relevant pathology or neof ormation. The Mann-Whitney U test was used for the evaluation of SUV_{max} to detect advanced dysplasia and large polyps. The Pearson's product-moment correlation (r) was used in the study of SUV_{max} and polyp size (mm). The Chi-squared test, 2 x 2 and HxK were used to evaluate the presence of a relevant pathology by gender, position, symptoms and type of primary tumor. CI was estimated at 95% and statistical significance was set at p < 0.05.

RESULTS

Of the 3,000 patients who underwent a PET-CT scan, 69% were male and 31% were female with a mean age of 65.77 years (\pm 11.2). Fifty-two uptakes (1.73%) were identified in the colon of 50 patients (Fig. 1). The location of uptakes were the rectum in ten cases (19.23%), sigmoid colon in 18 cases (34.62%), descending colon in seven cases (13.46%), transverse colon in one case (1.9%), ascending colon in ten cases (19.23%), cecum in five cases (9.62%) and the ileocolic anastomosis in one case (1.92%) (Table 1). A subsequent colonoscopy was performed in all cases with uptake, and a relevant pathology was found in 71.15% of cases (37 pathological findings, two during same colonoscopy); there were no mucosal alterations found by colonoscopy in 15 (28.8%) cases. The endoscopic lesions correspond to five neoplasms (13.5%) (four adenocarcinomas and one lymphoma), 30 polyps (81.1%) (13 tubulovillous adenomas, 12 tubulous adenomas, one villous adenoma, one hyperplastic polyp, one inflammatory polyp, two polyps with unknown pathological anatomy) and two inflammatory mucosal lesions (5.4%) (Table 2). The mean polyp size was 27 mm. There were no statistically significant differences between the SUV_{max} value with regard to the size (\geq 1 cm o < 1 cm) of polyps (p = 0.12) or the SUV_{max} value regarding the presence or absence of advanced dysplasia (p = 0.33).

The concordance between PET-CT and endoscopy location was high, with a *kappa* value of 0.90 (95% CI 0.83-0.93). The SUV_{max} value of all areas of incidental uptake varied between 2.8 and 21.1 g/ml, with a global average of 8.16 g/ml (typical deviation [TP] = 3.73). The SUV_{max} average of adenomatous polyps was 9.26 g/ml (TP = 4.53), neoplasia 11.7 g/ml (TP = 4.05), inflammatory lesions 10.5 g/ml (TP = 0.21) and 6.05 g/ml (TP = 1.78) in cases of colonoscopies without pathological findings (Fig. 2).

Significant differences were observed in the SUV_{max} value in neoplasms ($p = 0.03$) and adenomatous polyps ($p = 0.04$) compared to inflammatory lesions.

Primary neoplasms with the largest number of incidental uptake by PET-CT in the colon during the study were lung, non-Hodgkin lymphoma and breast (Table 3). A multivariate analysis using logistic regression did not identify predictive factors of endoscopy findings such as age, sex, uptake location, PET-CT indication and type of primary tumor, and the p values were 0.76, 0.51, 0.27, 0.19 and 0.19, respectively.

DISCUSSION

Fluorodeoxyglucose positron emission tomography (¹⁸F-FDG PET) is widely used in imaging tests of various malignancies for staging and surveillance. The integration of CT and PET images has increased the ability to locate regional areas of interest. However, the experience with PET-CT is limited and a consensus recommendation in terms of clinical application is still under assessment. Therefore, the use of colonoscopy and a histological study of colonic uptakes are the standard for subsequent evaluations (10,11).

In this study, the proportion of incidental uptake in the colon by PET-CT was 1.73%, which is similar to previously published studies (1,6,8,10). Colonoscopy revealed the presence of a relevant pathology in 37 (71.15%) of the 52 colonic uptake foci identified by PET-CT; the most common locations were in the rectum and sigmoid colon (51.9%). Of these 37 lesions, 13.51% were a neoplasm and 81.08% were polyps. These findings are also similar to those of previous studies (6,8,12-14). Nevertheless, our study demonstrated that despite a careful examination of the colonoscopy image, no lesions were found in 15 cases of ¹⁸F-FDG uptake. This represents a false-positive rate of 28.8% by PET-CT. These false-positive images could be due to intestinal inflammation, physiological uptake or imaging of gastrointestinal lymphoid tissue (15). Van Hoeij et al. (8) noted an absence of colonic lesions after colonoscopy in 38% of patients with focal uptakes in the colon by PET-CT. Peng et al. (16) noted and verified normal colonoscopies in 56% of patients evaluated with incidental colonic uptakes. Whereas studies conducted by Putora et al. (3) and Farquaharson et al. (17) reported a rate of 13.7 and 16.7% of normal colonoscopies in patients with incidental uptakes by PET-CT,

respectively.

With regard to the standard uptake value, a significantly higher mean value of SUV_{max} was found for malignant lesions compared to other types of lesions ($p = 0.03$). A mean SUV_{max} value of 11.7 g/ml (10.5-19.5) for incidental uptake corresponded to neoplasms, with a lower mean value for polyps and inflammatory lesions (9.26 g/dl and 10.5 g/dl, respectively). Furthermore, there were differences between the SUV_{max} values of incidental uptake related to the endoscopic detection of polyps, with a mean value of 9.26 g/ml *versus* 69 g/ml in those of a normal endoscopy. In previous studies, the mean SUV_{max} of neoplasms fluctuated between 5.7 and 17.3 g/ml (3,13,18,19). In the study conducted by Luboldt et al. (19), the mean SUV_{max} of neoplasms and advanced adenoma were significantly higher than those corresponding to false positives, although other studies found no significant differences in the mean SUV_{max} amongst the different groups assessed (3,6,13,18).

In our study, a multivariate analysis found no differences between sex, age, PET-CT indication, location of PET-CT uptake, or type of primary tumor in reference to the defined diagnostic categories. This is in accordance with previous studies by Treglia G et al. (6). However, Peng et al. (16) described variations between age and location of PET-CT uptake with regard to the presence of a neoplasm, polyp or normal colonoscopy, with relevant pathological findings predominating in cases ≥ 60 years old and lesions in the distal colon and rectum.

Our data identified significant differences between SUV_{max} values in cases of endoscopically confirmed lesions, especially neoplasms. This suggests that SUV_{max} values ≥ 11 g/dl may indicate a higher risk of malignancy and should be evaluated by colonoscopy as a priority. Van Hoeij et al. (8) established a cut-off point for SUV_{max} of ≥ 11.4 to distinguish between malignant and non-malignant lesions, which is very similar to our results. However, we cannot conclude that the SUV_{max} value is capable of differentiating between advanced adenomas without submucosal invasion and benign lesions. Therefore, all incidental uptake by PET-CT in the colon should be studied by colonoscopy, regardless of the SUV_{max} value. This statement also falls in line with previously published studies (3,6,8,13,14,16-18).

In our study, patients with a history of previously treated colorectal cancer were not excluded and there were a total of six cases. Four of them were investigated in order to re-stage a rectal neoplasm and images were obtained of the rectum that confirmed the presence of a neoplasm in a subsequent colonoscopy in two cases. In the third case, the image corresponded to an inflammatory lesion, and the colonoscopy was normal in the fourth case. The two cases with a history of colon cancer underwent a colonoscopy due to an increase in tumor markers; no relevant pathology was identified.

A limitation of our study is that it was not possible to calculate the sensitivity or specificity of PET-CT for the detection of colon lesions due to the fact that only colonoscopies were performed in patients with a positive PET-CT. Therefore, we were unable to determine the false negative rate. This issue will be addressed in future studies.

In conclusion, the results of our study suggest that malignant lesions in the colon have higher SUV_{max} values by PET-CT than other types of lesions. This could help to distinguish between a malignant and non-malignant pathology, with a cut-off point of ≥ 11 g/dl, which assists in the prioritization of endoscopic evaluation. However, the SUV_{max} is not able to differentiate between a benign pathology of advanced adenomas. Therefore, any PET-CT with colonic uptake should be further studied endoscopically. Thus, the SUV_{max} could help to define the urgency of a colonoscopy but not whether it should be performed or not.

REFERENCES

1. Weston BR, Iyer RB, Qiao W, et al. Ability of integrated positron emission and computed tomography to detect significant colonic pathology: the experience of a tertiary cancer center. *Cancer* 2010;116:1454-61. PMID: 20143447. DOI: 10.1002/cncr.24885
2. Lin M, Koo JH, Abi-Hanna D. Management of patients following detection of unsuspected colon lesions by PET imaging. *Clin Gastroenterol Hepatol* 2011;9:1025-32. PMID 21723237 DOI: 10.1016/j.cgh.2011.06.028

3. Putora RM, Müller J, Borovicka J, et al. Relevance of incidental colorectal FDG-PET-CT-enhanced lesions. *Onkologie* 2013;36:200-4. PMID: 23548969. DOI: 10.1159/000350302
4. Cook GJ, Fogelman I, Maisey MN. Normal physiological and benign pathological variants of 18-fluoro-2-deoxyglucose positron emission tomography scanning: potential for error in interpretation. *Semin Nucl Med* 1996;26:308-14. PMID: 8916319. DOI: 10.1016/S0001-2998(96)80006-7
5. Prabhakar HB, Sahani DV, Fischman AJ, et al. Bowel hot spots at PET-CT. *Radiographics* 2007;27(1):145-59. PMID: 17235004. DOI: 10.1148/rg.271065080
6. Treglia G, Calcagni ML, Rufini V, et al. Clinical significance of incidental focal colorectal F-fluorodeoxyglucose uptake: our experience and a review of the literature. *Colorectal Dis* 2011;14:174-80. PMID: 21689289. DOI: 10.1111/j.1463-1318.2011.02588.x
7. Beatty JS, Williams HT, Aldrige BA, et al. Incidental PET/CT findings in the cancer patient: how should they be managed? *Surgery* 2009;146:274-81. PMID: 19628085. DOI: 10.1016/j.surg.2009.04.024
8. Van HoeijFB, Keijsers RG, Loffeld BC, et al. Incidental colonic focal FDG uptake on PET/CT: can the maximum standardized uptake value (SUVmax) guide us in the timing of colonoscopy? *Eur J Nucl Med Mol Imaging* 2015;42(1):66-71. PMID: 25139518. DOI: 10.1007/s00259-014-2887-3
9. Steenkamp DW, McDonnell ME, Meibom S. Metformin may be associated with false-negative cancer detection in the gastrointestinal tract on PET/CT. *Endocr Pract* 2014;20(10):1079-83. PMID: 25100379. DOI: 10.4158/EP14127.RA
10. Fletcher JW, Djulbegovic B, Soares HP, et al. Recommendations on the use of 18F-FDG PET in oncology. *J Nucl Med* 2008;49:480-508. PMID: 18287273. DOI: 10.2967/jnumed.107.047787
11. Fuertes J, Montagut C, Bullich S, et al. Incidental focal uptake in colorectal location on oncologic 18FDG PET and PET/CT studies: histopathological findings and clinical significances. *Rev Esp Med Nucl Imagen Mol* 2015;34(2):95-101. PMID: 25263718. DOI: 10.1016/j.remn.2014.07.008

12. Jamar F, Buscombe J, Chiti A, et al. EANM/SNMMI guideline for 18F-FDG use in inflammation and infections. *J Nucl Med* 2013;54(4):647-58. PMID: 23359660. DOI: 10.2967/jnumed.112.112524
13. Gutman F, Alberini JL, Wartski M, et al. Incidental colonic focal lesions detected by FDG PET-TC. *AJR Am J Roentgenol* 2005;185:495-500. PMID: 16037527 DOI: 10.2214/ajr.185.2.01850495
14. Tatlidil R, Jadvar H, Bading JR, et al. Incidental colonic fluorodeoxyglucose uptake: correlation with colonoscopic and histopathologic findings. *Radiology* 2002;224:783-7. PMID: 12202714. DOI: 10.1148/radiol.2243011214
15. Drenth JP, Nagengast FM, Oyen WJ. Evaluation of (pre-)malignant colonic abnormalities: endoscopic validation of FDG-PET findings. *Eur J Nucl Med* 2001;28:1766-9. PMID: 11734913 DOI: 10.1007/s002590100645
16. Peng J, He Y, Xu J, et al. Detection of incidental colorectal tumours with 18F-labelled 2-fluoro-2-deoxyglucose positron emission tomography/computed tomography scans: results of a prospective study. *Colorectal Dis* 2011;13:e374-8. PMID: 21831098. DOI: 10.1111/j.1463-1318.2011.02727.x
17. Farquaharson AL, Chopra A, Ford A, et al. Incidental focal colonic lesions found on (18)Fluorodeoxyglucose positron emission tomography/computed tomography scan: further support for a national guideline on definitive management. *Colorectal Dis* 2012;14:e56-63. PMID: 21831171. DOI: 10.1111/j.1463-1318.2011.02760.x
18. Kei PL, Vikram R, Yeung HW, et al. Incidental finding of focal FDG uptake in the bowel during PET-CT: CT features and correlation with histopathologic results. *AJR Am J Roentgenol* 2010;194(5):W401-6. PMID: 20410385. DOI: 10.2214/AJR.09.3703
19. Luboldt W, Volker T, Wiedemann B, et al. Detection of relevant colonic neoplasms with PET/CT: promising accuracy with minimal CT dose and a standardized PET cut-off. *Eur Radiol* 2010;20(9):2274-85. PMID: 20503051. DOI: 10.1007/s00330-010-1772-0

Table 1. PET-CT uptake and colonoscopic location

<i>Rectum</i>	10 (19.23%)	7 (17.07%)
<i>Sigma</i>	18 (34.61%)	20 (48.78%)
<i>Descending colon</i>	7 (13.46%)	5 (12.19%)
<i>Transverse colon</i>	1 (1.92%)	2 (4.87%)
<i>Ascending colon</i>	10 (19.23%)	6 (14.63%)
<i>Cecum</i>	5 (9.61%)	1 (2.43%)
<i>Ileocolic anastomosis</i>	1 (1.92%)	0 (0%)

Table 2. SUV_{max} correlation with PET-CT uptake and histology

<i>Ascending colon</i>	19.5	ADC		
<i>Sigma</i>	18.5	TA	No	20
<i>Sigma</i>	16.7	TVA	No	30
<i>Sigma</i>	16	TVA	No	25
<i>Sigma</i>	14	TA	No	35
<i>Ascending colon</i>	13.5	TVA	Si	40
<i>Sigma</i>	13.4	TVA	No	20
<i>Sigma</i>	13.3	TVA	Si	35
<i>Descending colon</i>	12.2	TVA	No	17
<i>Rectum</i>	12.1	TA	No	50
<i>Cecum</i>	11.8	TA	No	30
<i>Ascending colon</i>	11	TA	Si	45
<i>Sigma</i>	10.8	ADC		
<i>Sigma</i>	10.8	TVA	Si	50
<i>Rectum</i>	10.5	ADC	-	-
<i>Sigma</i>	10.2	IP	No	16
<i>Cecum</i>	10	Lymphoma		
<i>Rectum</i>	9.9	NC		
<i>Sigma</i>	8.7	VA	Si	45
<i>Ascending colon</i>	8.5	TA	Si	40

<i>Rectum</i>	8.5	NC		
<i>Rectum</i>	8.1	NC		
<i>Sigma</i>	8	NC		
<i>Descending colon</i>	8	TA	Si	40
<i>Sigma</i>	7.9	NC		
<i>Cecum</i>	7.8	UHO		6
<i>Sigma</i>	7.8	TVA	No	25
<i>Sigma</i>	7.7	TVA	No	17
<i>Sigma</i>	7.7	ADC		
<i>Sigma</i>	7.1	TVA	No	25
<i>Ascending colon</i>	6.6	IML	No	10
<i>Sigma</i>	6.6	UHO		8
<i>Rectum</i>	6.2	NC		
<i>Ascending colon</i>	5.9	NC		
<i>Rectum</i>	5.6	IML	No	12
<i>Descending colon</i>	5.6	TA	No	30
<i>Rectum</i>	5.37	NC		
<i>Ileocolic anastomosis</i>	5.1	NC		
<i>Ascending colon</i>	5.1	NC		
<i>Descending colon</i>	4.7	NC		
<i>Ascending colon</i>	4.6	NC		
<i>Cecum</i>	4.6	NC		

<i>Ascending colon</i>	4	NC		
<i>Sigma</i>	3.8	TVA	Si	30
<i>Rectum</i>	3.6	TVA	Si	45
<i>Cecum</i>	3.4	TA	No	15
<i>Descending colon</i>	3.4	TA	No	10
<i>Descending colon</i>	3.3	TA	No	12
<i>Descending colon</i>	3.3	TA	No	18
<i>Rectum</i>	*	TVA	No	15
<i>Transverse colon</i>	*	NC		
<i>Ascending colon</i>	*	HP	No	10

ADC: adenocarcinoma; TA: tubulous adenoma; TVA: tubulovillous adenoma; VA: villous adenoma; IP: inflammatory polyp; IML: inflammatory mucosal lesion; HP: hyperplastic polyp; UHO: unknown histological origin; NC: normal colonoscopy. *Three incidental uptakes described during PET-CT, without specifying the SUV_{max} value.

Table 3. Reasons for performing a PET-CT

<i>Lung cancer</i>	12	2.4
<i>Non-Hodgkin lymphoma</i>	11	2.2
<i>Breast cancer</i>	7	1.4
<i>Solitary pulmonary nodule</i>	6	1.2
<i>Rectum cancer</i>	4	0.8
<i>Colonic cancer</i>	2	0.4
<i>Melanoma</i>	2	0.4
<i>Nasopharyngeal cancer</i>	1	0.2
<i>Metastatic disease with undetected primary lesion</i>	1	0.2
<i>Others (histiocytosis, genitourinary cancer)</i>	4	0.8

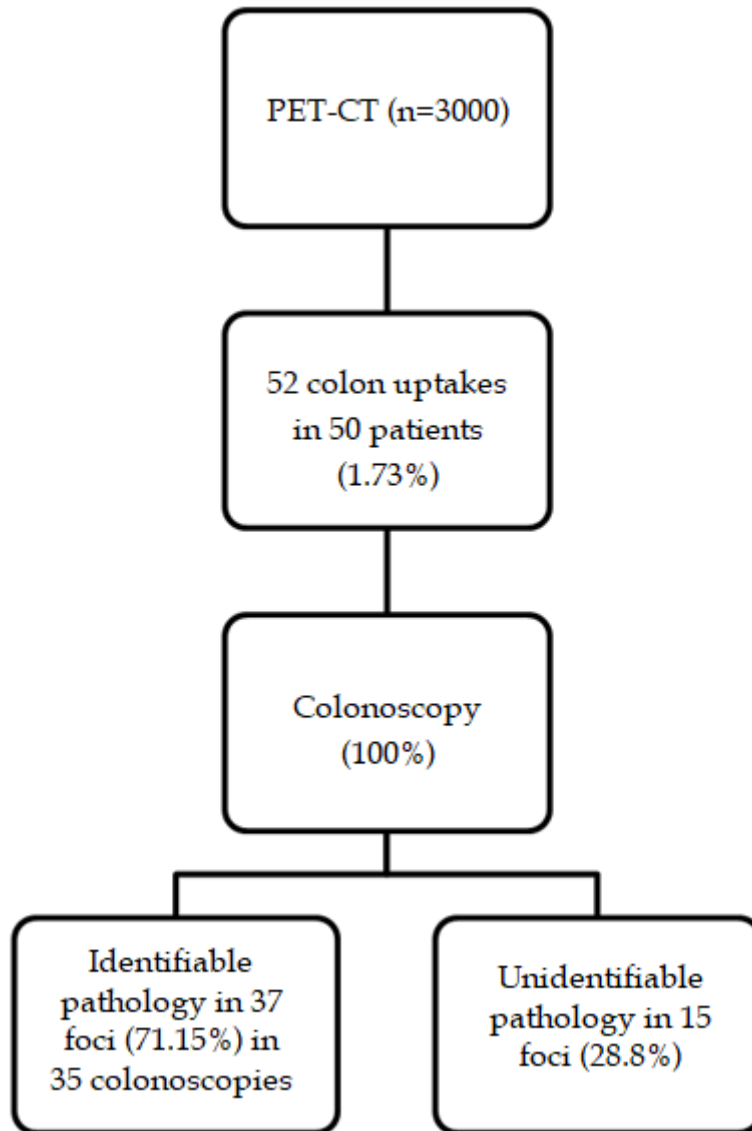


Fig. 1. Unexpected PET-CT uptake and pathology findings.

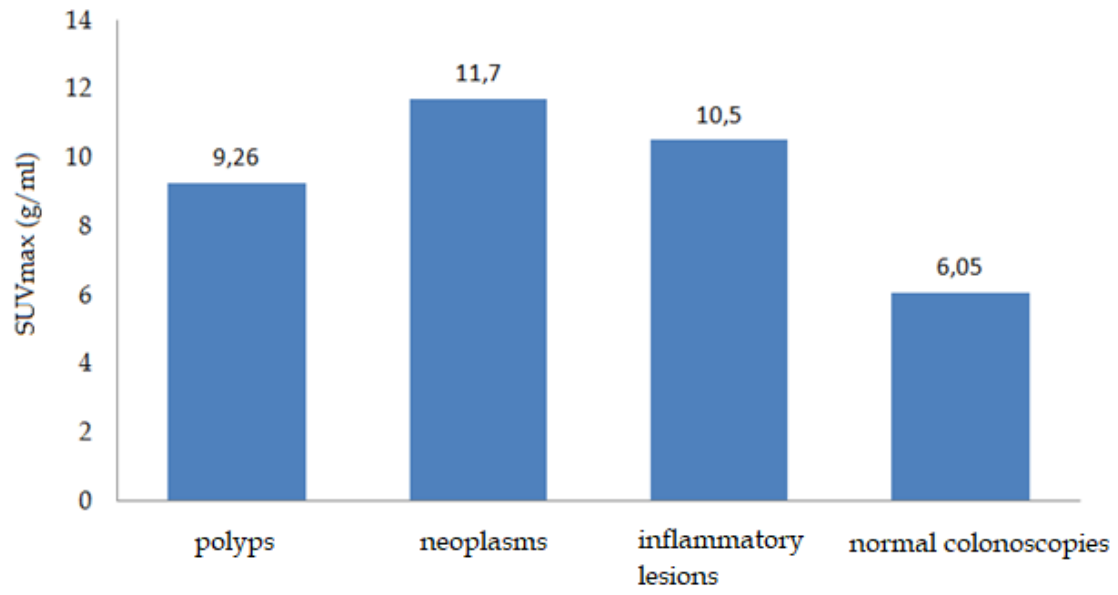


Fig. 2. SUV_{max} according to endoscopic findings.