

Title:
Tender red subcutaneous nodules in an adult female: a challenging diagnosis

Authors:
Juliana Moura da Costa, Rita Seara Costa,
Sofia Daniela Carvalho

DOI: 10.17235/reed.2018.5472/2018

Link: [PubMed \(Epub ahead of print\)](#)

Please cite this article as:
Costa Juliana Moura da, Costa Rita Seara ,
Carvalho Sofia Daniela . Tender red
subcutaneous nodules in an adult female: a
challenging diagnosis. Rev Esp Enferm Dig
2018. doi: 10.17235/reed.2018.5472/2018.

Enero 2017 • Volumen 109 • Número 1 • Páginas 1-86

Revista Española de Enfermedades Digestivas
THE SPANISH JOURNAL OF GASTROENTEROLOGY

Acceso al texto completo en: www.reed.es o www.sped.es

Factor de impacto 100Fu: JCR: 1.455-1248
SCR: 0.34-1026

ORGANO OFICIAL DE:
SOCIEDAD ESPAÑOLA DE PATOLOGÍA DIGESTIVA, SOCIEDAD ESPAÑOLA
DE ENDOSCOPIA DIGESTIVA Y ASOCIACIÓN ESPAÑOLA DE ECOGRAFÍA DIGESTIVA

SEPO

| | | |
|---|--|----|
| Editorial Colonic diverticular bleeding. Have we identified the risk factors for massive bleeding yet? J. W. Barton Valencia | Lesión de Bowdman: diagnóstico por gastroscopia R. Romero Guezo, M. N. Barco Irujo, M. Paz Nová y J. E. Domínguez Muñoz | 65 |
| Trabajos Originales Risk factors for severity and recurrence of colonic diverticular bleeding N. Aragón, P. Cabero, A. Arduini, M. Escobar and N. Guzmán | Notas Clínicas Cefas crisis in adults: a case report and review of the literature focusing in the prevention of relapsing syndrome M. de Alaveda-Nemón, V. L. Etxebarri-Caball and S. Latorre | 67 |
| Microsporidian and inflammatory bowel disease: the other Diogenes J. Bermejo, A. Aguiló, V. López-Cerdá, J. Cuervo, M. Acuña-Barca, M. Hernández-Serna, C. García, M. de la Cruz, D. Barrio and A. López-García | 3 Hemangiopericytoma peritonei. Una localización infrecuente de tumor mesodérmico I. Alonso Abad, J. M. García-Castro, L. Aguirre-Díaz, A. M. Quintana Berro y A. Colla-Morales | 69 |
| Influence of sustained 48-hr response on the regression of fibrosis and portal hypertension in cirrhotic HCV patients treated with antiviral therapy A. Riestra, J. Caballer, M. J. López-Alaiz, I. Latorre, M. T. Ariza, A. Galván, F. Castells, E. Fabrega and J. Crespo | 4 Hemofilia por erropia papilar intraductal C. Pérez-Carpas, A. Etxebarri-Barbero, M. A. Paredes-Capó, J. Arangul-Arribas y C. García-Delgado | 70 |
| Malnutrition risk questionnaire combined with body composition measurement in malnutrition screening in inflammatory bowel disease A. A. Cortés, A. Muñoz, Z. Pili, I. Pall and P. Malvar | 5 Endoscopic removal of intubated large hepatic polyp: a case report M. Oquendo and C. Satoru Muramatsu | 73 |
| A survey-based analysis of endoscopic quality indicators compliance among Spanish endoscopists I. Fernández-Cruz, F. Argüelles, P. Alonso, J. Salas and S. Soriano | 6 Mesenteric schistosomiasis: an unusual cause of abdominal mass A. Tapia-Palacio, M. R. Ramos-Vázquez, J. C. Cordero-Ramos, J. Cordero-Lafont and L. Carballo-Pérez | 76 |
| Revisión Endoscopic resection of colonic polyps in patients on antiplatelet therapy: an evidence-based guideline for clinicians G. Piana, M. Sostero-Salín, C. Salinas, F. Day and M. J. Cuervo | Cartas al Editor Neoplasia neuroendocrina-mucosa, un tumor poco habitual M. de Barco Nová, J. Santos-Fernández y M. C. Ramos-Rodríguez | 79 |
| Indicadores en Patología Digestiva Neutrofilos de la arteria mesentérica superior: una causa infrecuente de obstrucción intestinal J. Sempere Jaquez, P. Abadía-Serna y J. C. García-Pérez | 7 Presentación intestinal de tuberculosis por radioterapia previa: diagnóstico asociado a cambios de Biavasol, patología infecciosa y poco conocida Y. Pardo-Vargas, D. M. Aparicio y L. A. Alvarez | 80 |
| Neumatosis cística intestinal A. F. Romero-Muñoz y R. Barrio-Zelga | 8 Perforación endoscópica: revisión for an actualized patient with multiple esophageal diverticula Y. Se, H. Zhu and D. Liu | 81 |
| Tumores de Wilms a pírcia autoinmunitaria C. Oña-Solís, C. L. Hernández-Segú, J. Pineda-Rodríguez y A. M. González-Fernández | 9 Actualización y endoscopia: endoscopia, endoscopia, endoscopia C. Sánchez-Jiménez, J. Guevara-Nieto y J. A. Acosta-Paredes | 81 |
| Endoscopic retrieval of trichobezoars in a schizophrenic patient J. L. Bermejo-Hernández, M. E. Torres-Castro and M. Torres-Rodríguez | 10 Perforación múltiple de divertículos de intestino delgado en paciente con síndrome de Ulcers-Duodenitis R. Fernández-Cruz, A. Burgos-Castro y E. Palencia-López | 83 |
| All that glitters is not gold. A different cause for an "alkaline vomit" A. Pineda, M. Soto, J. Vitor-Barco and G. Navarro | 11 Algoritmo actualizado sobre manifestación paraneoplásica de un adenoma actínico gástrico J. Alvarez-Castro, F. Fernández-Serrano y J. de la Fuente-Aguado | 83 |
| | 12 Revisores 2016 | 85 |

ARAN

www.reed.es

This is a PDF file of an unedited manuscript that has been accepted for publication. As a service to our customers we are providing this early version of the manuscript. The manuscript will undergo copyediting, typesetting, and review of the resulting proof before it is published in its final form. Please note that during the production process errors may be discovered which could affect the content, and all legal disclaimers that apply to the journal pertain.

CE 5472

Tender red subcutaneous nodules in an adult female: a challenging diagnosis

Juliana M. Costa¹, Rita Costa¹ and Sofia Carvalho²

Departments of ¹Gastroenterology and ²Pathology. Hospital de Braga. Braga, Portugal

Correspondence: Juliana M. Costa

e-mail: julianamcosta87@gmail.com

Key words: Endoscopic pancreatitis. Pancreatic panniculitis. Adipocyte necrosis.

Dear Editor,

Pancreatic panniculitis is an uncommon and rare skin complication of systemic fat necrosis associated with pancreatitis *post-ampullectomy*. Besides the rarity of the condition, the clinical history and physical examination for diagnosis is also important.

Case report

A 74-year-old female underwent an endoscopic mucosal resection and ampullectomy of a type 0-IIa (Paris Classification) duodenal lesion that involved the major papilla. The procedure was complicated due to pancreatitis, and two days later the patient presented multiple nodular erythematous and purplish skin lesions (Fig. 1A) in the lower limbs. These were tender and painful on palpation and the largest lesion measured nearly 3 cm in diameter. The patient had no past history of inflammatory or renal disorder, trauma or infection. Hyperuricemia and alpha-1 antitrypsin deficiency were not present. The skin lesions resolved spontaneously after four days with the concomitant improvement of the pancreatitis. Biopsies of the lesions confirmed a diagnosis of pancreatic panniculitis (Fig. 1B).

DISCUSSION

Pancreatic panniculitis is an inflammatory condition of the subcutaneous fat which can develop concomitantly with pancreatic diseases (0.3-3% of all pancreatic diseases) (1). The etiology is unknown but fat necrosis following the release of pancreatic enzymes into the bloodstream has been considered (2). Panniculitis manifests as tender erythematous or violaceous subcutaneous nodules usually located in the lower limbs but can also spread over the trunk and upper limbs. These lesions may ulcerate and can become infected (3). The skin manifestations are independent of the severity of the pancreatitis and can occur at any time during its clinical course (4). The diagnosis is based on the clinical history and physical examination, and skin biopsies confirm the diagnosis (5). The treatment is supportive and skin nodules usually disappear following the resolution of the pancreatic inflammation (1).

References

1. Dahl PR, Su WP, Cullimore KC, et al. Pancreatic panniculitis. *J Am Acad Dermatol* 1995;33:413-7. DOI: 10.1016/0190-9622(95)91385-8
2. García-Romero D, Vanaclocha F. Pancreatic panniculitis. *Dermatol Clin* 2008;26:465-70. DOI: 10.1016/j.det.2008.05.009
3. Tran KT, Hughes S, Cockerell CJ, et al. Tender erythematous plaques on the legs. Pancreatic panniculitis (PP). *Clin Exp Dermatol* 2010;35:e65-6. DOI: 10.1111/j.1365-2230.2009.03457.x
4. Makhoul E, Yarbeck C, Urbain D, et al. Pancreatic panniculitis: a rare complication of pancreatitis secondary to ERCP. *Arab J Gastroenterol* 2014;15(1):38-9. DOI: 10.1016/j.ajg.2013.11.005
5. Tran KT, Hughes S, Cockerell CJ, et al. Tender erythematous plaques on the legs. Pancreatic panniculitis (PP). *Clin Exp Dermatol* 2010;35:e65-6. DOI: 10.1111/j.1365-2230.2009.03457.x

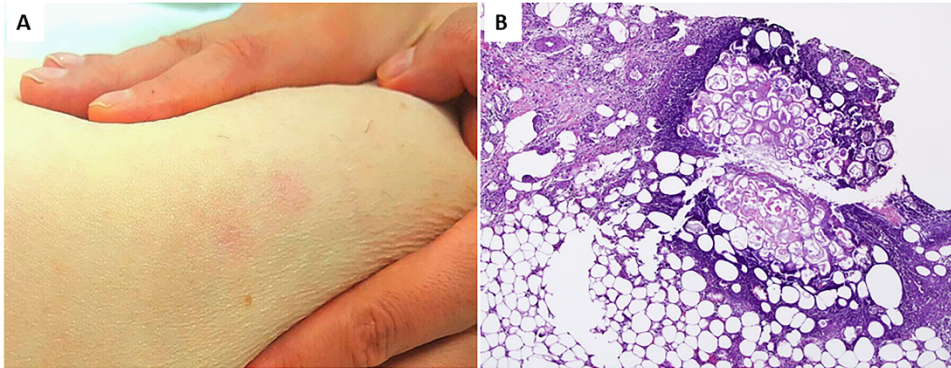


Fig. 1. A. An abdominal physical examination revealed multiple nodular erythematous and purplish skin lesions on the lower limbs, which were tender and painful on palpation; the largest lesion measured nearly 3 cm in diameter. B. Histological examination of skin lesion biopsies showed a predominant lobular panniculitis with enzymatic degeneration of adipocytes and peripheral neutrophilic inflammation. Discrete septal panniculitis was also observed (H&E, 40x).