

Title:

Colorectal penetration by two intrauterine devices

Authors:

Mariana Tavecchia, Aurora Burgos García, Pedro de María Pallares

DOI: 10.17235/reed.2019.5974/2018

Link: [PubMed \(Epub ahead of print\)](#)

Please cite this article as:

Tavecchia Mariana, Burgos García Aurora, de María Pallares Pedro. Colorectal penetration by two intrauterine devices. Rev Esp Enferm Dig 2019. doi: 10.17235/reed.2019.5974/2018.



This is a PDF file of an unedited manuscript that has been accepted for publication. As a service to our customers we are providing this early version of the manuscript. The manuscript will undergo copyediting, typesetting, and review of the resulting proof before it is published in its final form. Please note that during the production process errors may be discovered which could affect the content, and all legal disclaimers that apply to the journal pertain.

Accepted

IPD 5974

Colorectal penetration by two intrauterine devices

Mariana Tavecchia, Aurora Burgos-García and Pedro de María-Pallarés

Department of Gastroenterology. Hospital Universitario La Paz. Madrid, Spain

Correspondence: Mariana Tavecchia

e-mail: marianatavecchia@gmailcom

CASE REPORT

A colonoscopy was performed as part of a colorectal screening program on a 77-year-old female with positive fecal occult blood test. During withdrawal, two metallic elongated foreign bodies, around 20 mm in length were found pinned into the transverse colon (Fig. 1) and rectal wall (Fig. 2). A computed tomography with multiplanar reconstruction showed two metallic density T-shaped foreign bodies that resembled intrauterine devices (IUDs) that penetrated the intestinal wall (Fig. 3), which ruled out other complications. The patient confirmed a previous loss of an IUD device 35 years previously and underwent a second IUD insertion a few years later. She refused another colonoscopy for endoscopic removal as she did not have any symptoms in the past.

DISCUSSION

In conclusion, uterine perforation is a rare but potentially serious complication (1). We report the first ever reported case in which two different IUDs were found penetrating the colorectal wall. Although it is a general recommendation to remove all migrated uterine devices in order to avoid complications (2,3), leaving the device in place in asymptomatic patients should also be considered.

REFERENCES

1. McCombie JJ, Le Fur R. Colonoscopic removal of an ectopic intrauterine device. ANZ J Surg 2012;82(5):369-70. DOI: 10.1111/j.1445-2197.2012.06031.x
2. Huertas-Velasco MA, Gómez-Rubio M. Endoscopic removal of intrauterine device penetrated through the rectal wall. Rev Esp Enferm Dig 2012;104(8):432-3. DOI: 10.4321/S1130-01082012000800007
3. Lee JE, Park KS, Kim ES, et al. Removal of a lost intrauterine device by colonoscopy after a successful full-term delivery (with video). Gastrointest Endosc 2010;72(4):898-900. DOI: 10.1016/j.gie.2010.01.043

Accepted Article

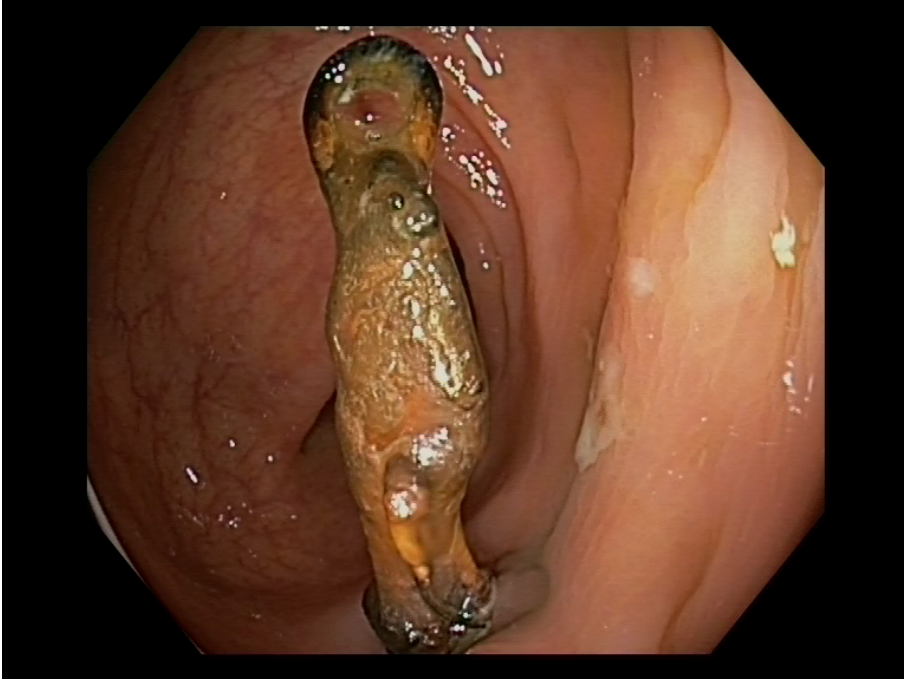

Fig. 1. Intrauterine device penetrating the transverse colon.

Accepted

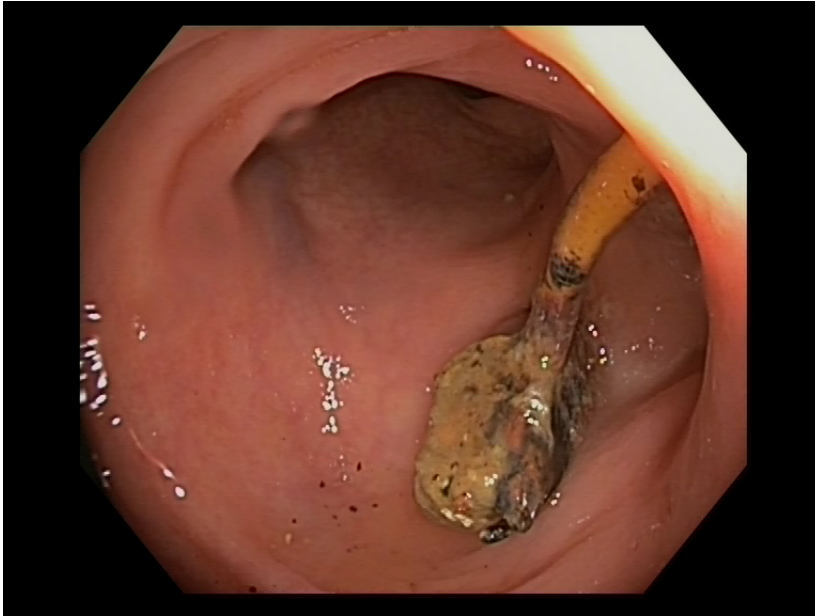


Fig. 2. Second intrauterine device found in rectum.

Accepted

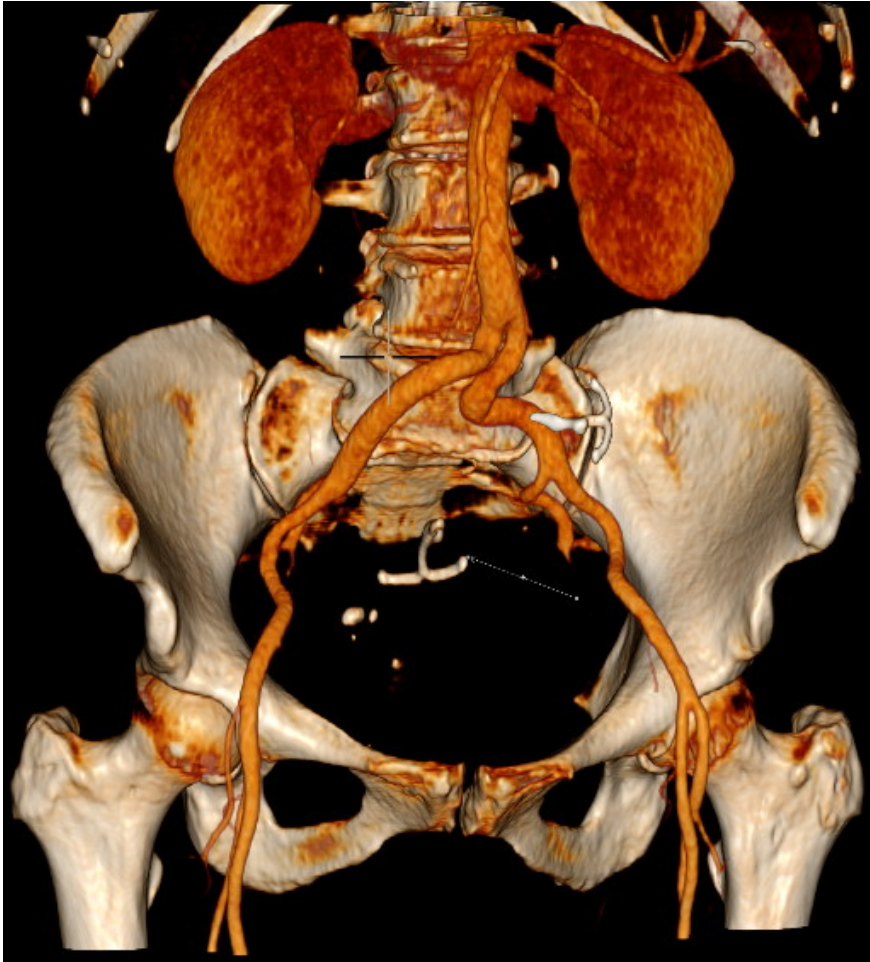


Fig. 3. Multiplanar 3D reconstruction of computed tomography showing both intrauterine devices.

Acceler