

Title:

**Vedolizumab for treatment of chronic refractory pouchitis:
a systematic review with pool analysis**

Authors:

Davide Giuseppe Ribaldone, Rinaldo Pellicano, Giorgio
Maria Saracco, Mario Morino, Marco Astegiano

DOI: 10.17235/reed.2019.6336/2019

Link: [PubMed \(Epub ahead of print\)](#)

Please cite this article as:

Ribaldone Davide Giuseppe, Pellicano Rinaldo, Saracco
Giorgio Maria, Morino Mario, Astegiano Marco.
Vedolizumab for treatment of chronic refractory pouchitis:
a systematic review with pool analysis. Rev Esp Enferm Dig
2019. doi: 10.17235/reed.2019.6336/2019.



This is a PDF file of an unedited manuscript that has been accepted for publication. As a service to our customers we are providing this early version of the manuscript. The manuscript will undergo copyediting, typesetting, and review of the resulting proof before it is published in its final form. Please note that during the production process errors may be discovered which could affect the content, and all legal disclaimers that apply to the journal pertain.

Accepted Article

REV 6336

Vedolizumab for treatment of chronic refractory pouchitis: a systematic review with pool analysis

Davide Giuseppe Ribaldone¹, Rinaldo Pellicano², Giorgio Maria Saracco³, Mario Morino¹ and Marco Astegiano²

¹Department of Surgical Sciences. Università di Torino. Turin, Italy. ²Unit of Gastroenterology. Ospedale Molinette. Turin, Italy. ³Department of Medical Sciences. Università di Torino. Turin, Italy

Correspondence: Davide Giuseppe Ribaldone. Department of Surgical Sciences. Università di Torino. Turin, Italy
e-mail: davrib_1998@yahoo.com

ABSTRACT

Background and objectives: about 1%-2% of patients with chronic refractory pouchitis, in the context of ulcerative colitis, end up with a permanent ileostomy. The aim of this systematic review was to collect all published studies involving patients treated with vedolizumab for chronic refractory or antibiotic-dependent pouchitis and then pool the data regarding the effectiveness of this therapeutic strategy.

Methods: a MEDLINE and Web of Science search of all studies published in English until March 17, 2019 was conducted using the terms “vedolizumab and pouchitis”.

Results: seven studies with a total of 44 patients with chronic pouchitis were included. Twenty-three out of 44 patients (52.3%) had undergone previous treatment with anti-tumor necrosis factor (TNF) drugs. At week 12, 33 out of 44 patients (75%) reported clinical improvement. Endoscopic improvement, evaluated within 6 months of the start of vedolizumab therapy, was obtained in 28 out of the 38 patients in whom such data were available (73.7%).

Conclusions: this first systematic review published in the literature on this issue suggests that vedolizumab has significant efficacy in chronic refractory or antibiotic-dependent pouchitis, also in patients who failed to respond to other treatments including those with anti-TNF agents.

Keywords: Anti-integrin. Anti-TNF. Ulcerative colitis. Surgery.

INTRODUCTION

Ulcerative colitis (UC) is a chronic inflammatory bowel disease characterized by bloody diarrhoea, abdominal cramps, and fatigue (1). Since in the last decades its therapy has been notably improved, UC has shifted from being a disease with high mortality rates, in case of severe flare-ups, to a disease for which numerous classes of drugs are available, including mesalazine, corticosteroids, monoclonal antibodies, and so-called small molecules (2).

Unfortunately, even today 10% to 15% of patients with UC require surgery either after failing to respond to medical therapy or because of their developing dysplasia. The surgical treatment of choice for most of these patients is proctocolectomy with ileal pouch-anal anastomosis (IPAA) (3).

Despite the fact that UC is, by definition, a disease limited to the colon and rectum, in theory healed by total proctocolectomy, many patients develop nonspecific inflammation in the pouch, the so-called "pouchitis", leading to symptoms such as pain, urgency, and increased stool frequency, with estimated incidences ranging from 46% to 82% (4). The pathophysiology of pouchitis remains poorly understood, despite its being the most common long-term complication after IPAA. An increase in bacterial levels and dysbiosis in the ileal reservoir seem to be among the main contributors (5). Inflammation of the pouch after IPAA can significantly impact quality of life in these patients and could be difficult to treat. Treatments for pouchitis include probiotics (6) (i.e., VSL#3) (7), antibiotics (i.e., ciprofloxacin, metronidazole), and topical therapy (8). However, about 10% to 15% of patients with acute pouchitis do not respond to these treatments and develop chronic pouchitis, which is defined by symptoms persisting for more than 4 weeks. These patients often require rotating courses of antibiotics as well as maintenance therapy. Steroids (i.e., budesonide) (9), immunosuppressants (i.e., azathioprine) (10), and anti-tumor necrosis

factor (TNF) (i.e., infliximab, adalimumab) agents (11,12) are some of the options used to treat chronic pouchitis. Studies including small numbers of patients (often fewer than 20), and mostly retrospective in design, have demonstrated that infliximab appears to have good clinical effectiveness in selected patients with pouchitis, achieving up to 80% of short-term and around 50% of long-term responses. However, some data suggest that, in some patients treated with anti-TNF agents for chronic pouchitis, the result may potentially consist of a delay for inevitable surgery rather than a meaningful impact on the course of disease (13). In fact, with these drugs, 60%-80% of patients achieve a clinical response or remission, but 1%-2% of them end up with a permanent ileostomy (14).

Thus, despite the introduction of biological therapies, many patients with pouchitis remain refractory to available treatments, requiring surgical excision of the pouch or permanent diversion. There is, therefore, room for new therapeutic options in the patients who fail to respond to commonly used drugs in order to try and avoid definitive ileostomy. In this regard, the potential role of bacteria in the pathogenesis of pouchitis, confirmed both by the efficacy of antibiotic treatment during active pouchitis and the benefit induced by using probiotics in the maintenance of remission, has opened the way to one of the newer biological drugs approved for UC, vedolizumab. Dysbiosis, defined as an unfavourable alteration of the quantitative and qualitative composition of intestinal microbiota, contributes to the attraction of leucocyte adhesion by integrin-MAdCam interaction (15). Vedolizumab is a gut-selective, humanized monoclonal antibody of the immunoglobulin G1 type against alpha 4-beta 7 integrin, moderating gut lymphocyte trafficking (blocking the link between alpha 4-beta 7 integrin and MAdCam), and is approved for the treatment of both UC and Crohn's disease.

To date, few studies are available about the efficacy of vedolizumab in the setting of chronic pouchitis (16-18), and no systematic review has been published. The aim of this systematic review is to collect all the published data about patients treated with vedolizumab for chronic refractory pouchitis and to pool together those dealing with the effectiveness of this therapeutic strategy.

METHODS

Articles published in English on the use of vedolizumab for the treatment of chronic refractory pouchitis were identified through PubMed and Web of Science ("All databases")

searches using the terms “vedolizumab and pouchitis”. The final date of the search was March 17, 2019.

Reference lists from published articles were also employed, such as citing articles on PubMed Central. The titles of these publications and their abstracts were scanned in order to eliminate duplicates and irrelevant articles.

The inclusion criteria were:

- a) confirmed diagnosis of UC subjected to proctocolectomy with IPAA;
- b) use of vedolizumab treatment for chronic refractory antibiotic-dependent pouchitis;
- c) availability of data about age, gender, percentage of patients treated with an anti-TNF for pouchitis, and percentage of clinical (as defined in each case report and case series) and endoscopic response.

The exclusion criteria were:

- a) Crohn’s disease of the pouch;
- b) review articles.

There was no restriction regarding study design type or sample size.

Two authors (D.G.R. and R.P.) independently reviewed the titles and abstracts of the references retrieved by the literature search, and selected the potentially relevant studies. The full-text version of the selected studies was then assessed by the two authors to determine whether the inclusion criteria were met. Differences in opinion were solved by discussion until consensus was reached. If agreement failed to be reached, a third author (A.M.) was consulted.

Since only retrospective case series and case reports regarding vedolizumab efficacy in chronic refractory pouchitis without a comparator are available in the literature, all the studies in agreement with the inclusion and exclusion criteria were included in the systematic review and in the pooled analysis, without a quality analysis of each study or a meta-analysis.

Statistical analysis

The number of patients, their age and gender, the use of anti-TNF drugs for pouchitis, and data related to clinical and endoscopic improvement were collected in a datasheet and pool analysed.

Data were tested for normality using the D'Agostino-Pearson test. If these were not normally distributed, the median (range) was reported, otherwise the mean (range) was reported. Categorical variables were reported as number and percentage.

The statistical analysis was conducted using the MedCalc Statistical Software version 18.9.1 (MedCalc Software bvba, Ostend, Belgium; <http://www.medcalc.org>; 2018).

RESULTS

Figure 1 represents a flow diagram showing study parameters such as identification, screening, eligibility, and number of included studies.

In the year 2017, Schmid et al. published the first case report of a pouchitis treated with vedolizumab (16). A 54-year-old male with a history of IPAA for refractory UC developed pouchitis 14 years later. Pouchitis was refractory to treatment with metronidazole, VSL#3, budesonide, mesalamine, hydrocortisone rectal foam, and finally faecal microbiota transplantation. The patient was switched to vedolizumab therapy and showed sustained clinical and endoscopic responses (after 6 months from the start of treatment) (Table 1).

In the same year, Coletta et al. published a case report regarding a 33-year-old man with anti-TNF-refractory chronic pouchitis treated with vedolizumab (17). The patient, due to unresponsiveness to medical management, eventually underwent IPAA. As soon as 3 months after ileostomy closure chronic pouchitis developed; it was refractory to antibiotics and anti-TNF agents. Thus, vedolizumab was started leading to a marked clinical improvement, which was maintained up to the end of follow-up (week 34). Compared with baseline, an endoscopy performed at week 14 documented a complete resolution of erosions and ulcerations.

Mir et al. published the case of a 41-year-old female who underwent IPAA due to refractory UC (18). Two years after IPAA the patient developed pouchitis and was treated firstly with trimethoprim-sulfamethoxazole and then with rifaximin, obtaining a partial response (stool blood resolved but she continued to have from 10 to 20 bowel movements daily). After initiation of vedolizumab clinical improvement was reported at week 6, with a decreased frequency of bowel movements to four to six daily without stool blood. Abdominal pain also improved. A repeat pouchoscopy demonstrated only a single linear ulcer and a healthy pouch mucosa after 6 months from the initiation of vedolizumab.

In 2018, Martins et al. published a case report regarding a 20-year-old woman who underwent IPAA due to refractoriness to infliximab. One year later a relapsing chronic pouchitis was diagnosed and treated with antibiotics and oral budesonide, obtaining a partial response. Subsequently, adalimumab was started without remission. Hence, the authors employed vedolizumab. With the latter agent the patient reported clinical improvement at week 12, and a pouchoscopy performed after 6 months on treatment revealed only mucosal oedema (19).

Orfanoudaki et al. published a case report about a 22-year-old female with a history of IPAA due to refractory UC. The patient was diagnosed with pouchitis 1 year after surgery. Initially, she was treated with antibiotics and prednisolone, then with infliximab followed by adalimumab, both discontinued after an early severe allergic reaction and a loss of response attributed to antibody formation, respectively. Vedolizumab was subsequently initiated, together with a single course of antibiotics, and the patient experienced clinical amelioration. A new pouchoscopy, performed at week 33, showed significant improvement, with scars and small ulcerations (20).

Bär et al. published the first retrospective case series about the efficacy of vedolizumab in the treatment of chronic and antibiotic-dependent or refractory pouchitis (21). The authors included 20 patients, of whom 12 men, with a median age of 22.5 years; all of them underwent IPAA due to refractory UC (median duration from IPAA to pouchitis: 1 year). Eleven patients had experienced at least one treatment with anti-TNF agents for pouchitis. All patients were treated with vedolizumab, and at week 14 clinical improvement was achieved in 13 out of 20 of them. In 14 patients the endoscopic outcome was assessed at week 14, with a response being achieved in 9 of them. The pouch disease activity index (PDAI), a validated score used to assess the endoscopic effectiveness of a drug, dropped from 10 to 3 (normal range, 0-18).

Another retrospective case series was published in the year 2018. This study included 4 patients previously described in the first case series published about vedolizumab efficacy in refractory chronic pouchitis (22), and a total of 19 patients were analysed (23). Ten of them were male and the mean age of the cohort was 26.7 years. Nine patients were treated with anti-TNF agents after colectomy and IPAA. Fifteen patients had at least a clinical response to vedolizumab, 14 had both endoscopic and clinical responses, and 4 patients underwent surgery because of drug therapy failure.

Pooled analysis

A total of 44 patients met the inclusion criteria of this systematic review. Mean age was 25.6 years; 24 patients were male (54.5%) and 20 were female (45.5%). Twenty-three out of 44 patients (52.3%) had a previous experience with anti-TNF agents for chronic pouchitis.

Clinical improvement at week 12 was obtained in 33 out of 44 patients (75%) (Fig. 2). Endoscopic improvement, evaluated within 6 months of the start of vedolizumab therapy, was obtained in 28 out of the 38 patients in whom data were available (73.7%) (Fig. 3).

DISCUSSION

As mentioned in the introduction, since dysbiosis is a key factor for pouchitis development, and contributes to the attraction of leucocytes that will undergo adhesion by the integrin-MAdCam interaction (15), vedolizumab, a drug that blocks alpha 4-beta 7 integrin, could be a drug potentially effective in this setting. In theory, vedolizumab could represent a good option for this unmet need but data on the treatment of chronic pouchitis with this drug are limited as of today.

Our study represents the first systematic review with a pooled analysis focusing on the effectiveness of vedolizumab in the treatment of chronic refractory pouchitis. We included 7 studies, of which 2 were retrospective case series and 5 were case reports, with a total of 44 patients. We excluded patients treated for Crohn's disease of the pouch.

Regarding the epidemiological characteristics of the cohort treated so far, gender was almost equally distributed (54.5% were male), and mean age was 25.6 years. Almost half of these patients (52.3%) had been previously treated for chronic pouchitis with at least 1 anti-TNF drug, after failure of conventional first-line therapies (probiotics, antibiotics, budesonide).

Considering the difficulties entailed by the population treated, the 75% rate of clinical improvement (as defined by each included study) and the 73.7% rate of endoscopic improvement may be considered to be more than merely satisfactory. In addition to these favourable results, a gut-specific anti-integrin therapy like vedolizumab has the benefit of being potentially safer than systemic therapies, and could therefore be the ideal drug to be used also for a maintenance strategy, which is often needed in these patients.

Since no comparative studies between vedolizumab and anti-TNF agents as salvage therapy before definitive ileostomy in chronic pouchitis are available, vedolizumab (because of its higher cost) should be positioned after anti-TNF drugs have failed or when their use is contraindicated.

Increasing attention to the use of the newer biological agents and the possible incorporation of future small-molecule therapies hold great promise in closing the remaining therapeutic gap still present in the treatment of chronic pouchitis. Furthermore, an efficacious use of vedolizumab would not only provide a significant therapeutic advance but would also offer further insights into the underlying pathogenesis of pouchitis (see the key role of dysbiosis). Some criticisms must be raised towards our systematic review. Its main limitation is that only a small number of patients have been treated until now with vedolizumab for chronic refractory pouchitis, but these data are of paramount importance for a condition with such a high impact on quality of life. Furthermore, these patients had a history of severe chronic illness, with lack of response to numerous treatment lines and previous surgical colectomy. Another criticism arises by the fact that the definition of clinical improvement represents a weak outcome, but the features of this extreme difficult-to-treat population and the evidence of a 73.7% rate of endoscopic improvement reinforce these efficacy data of vedolizumab. One important limitation of this systematic review is linked to the design of the included studies (case reports and case series): no study using a comparison group was found and a potential publication bias, due to lack of studies publishing negative results, should be taken into account. Finally, given the small sample sizes, sub-analyses about predictors of vedolizumab efficacy in this setting could not be undertaken.

In conclusion, our systematic review suggests that vedolizumab has significant efficacy in chronic refractory or antibiotic-dependent pouchitis, also in patients who failed to respond to other treatment modalities, including anti-TNF agents.

Larger studies with a higher number of patients are required to confirm these findings. A phase-4 study aiming to evaluate the efficacy and safety of vedolizumab in the treatment of chronic pouchitis (EARNEST) is already in progress.

REFERENCES

1. Feagan BG, Rutgeerts P, Sands BE, et al. Vedolizumab as Induction and Maintenance Therapy for Ulcerative Colitis. *N Engl J Med* 2013;369(8):699-710. DOI: 10.1056/NEJMoa1215734
2. Actis GC, Pellicano R, Ribaldone DG. A Concise History of Thiopurines for Inflammatory Bowel Disease: from Anecdotal Reporting to Treat-to-Target Algorithms. *Rev Recent Clin Trials* 2018;1:4-9.
3. Fazio VW, Kiran RP, Remzi FH, et al. Ileal pouch anal anastomosis: analysis of outcome and quality of life in 3707 patients. *Ann Surg* 2013;257(4):679-85. DOI: 10.1097/SLA.0b013e31827d99a2
4. Barnes EL, Herfarth HH, Sandler RS, et al. Pouch-Related Symptoms and Quality of Life in Patients with Ileal Pouch–Anal Anastomosis. *Inflamm Bowel Dis* 2017;23(7):1218-24. DOI: 10.1097/MIB.0000000000001119
5. Landy J, Al-Hassi HO, McLaughlin SD, et al. Etiology of pouchitis. *Inflamm Bowel Dis* 2012;18(6):1146-55. DOI: 10.1002/ibd.21911
6. Gionchetti P, Rizzello F, Helwig U, et al. Prophylaxis of pouchitis onset with probiotic therapy: a double-blind, placebo-controlled trial. *Gastroenterology* 2003;124(5):1202-9. DOI: 10.1016/S0016-5085(03)00171-9
7. Gionchetti P, Calabrese C, Lauri A, et al. The therapeutic potential of antibiotics and probiotics in the treatment of pouchitis. *Expert Rev Gastroenterol Hepatol* 2015;9(9):1175-81. DOI: 10.1586/17474124.2015.1072046
8. Ribaldone DG, Resegotti A, Astegiano M. The therapy of chronic pouchitis. *Minerva Gastroenterol Dietol*; 2019. DOI: 10.23736/S1121-421X.18.02551-5
9. Gionchetti P, Rizzello F, Poggioli G, et al. Oral budesonide in the treatment of chronic refractory pouchitis. *Aliment Pharmacol Ther* 2007;25(10):1231-6. DOI: 10.1111/j.1365-2036.2007.03306.x
10. Gionchetti P, Amadini C, Rizzello F, et al. Review article: treatment of mild to moderate ulcerative colitis and pouchitis. *Aliment Pharmacol Ther* 2002;16(Suppl 4):13-9. DOI: 10.1046/j.1365-2036.16.s4.3.x
11. Acosta BM, García-Bosch O, Souto R, et al. Efficacy of infliximab rescue

- therapy in patients with chronic refractory pouchitis: A multicenter study. *Inflamm Bowel Dis* 2012;18(5):812-7. DOI: 10.1002/ibd.21821
12. Barreiro-de Acosta M, García-Bosch O, Gordillo J, et al. Efficacy of adalimumab rescue therapy in patients with chronic refractory pouchitis previously treated with infliximab. *Eur J Gastroenterol Hepatol* 2012;24(7):756-8. DOI: 10.1097/MEG.0b013e3283525a7b
13. Segal JP, Penez L, Mohsen Elkady S, et al. Long term outcomes of initial infliximab therapy for inflammatory pouch pathology: a multi-Centre retrospective study. *Scand J Gastroenterol* 2018;1-8.
14. Meagher AP, Farouk R, Dozois RR, et al. J ileal pouch-anal anastomosis for chronic ulcerative colitis: complications and long-term outcome in 1310 patients. *Br J Surg* 1998;85(6):800-3. DOI: 10.1046/j.1365-2168.1998.00689.x
15. Hammer HF. Gut Microbiota and Inflammatory Bowel Disease. *Dig Dis* 2011;29(6):550-3. DOI: 10.1159/000332981
16. Schmid M, Frick J-S, Malek N, et al. Successful treatment of pouchitis with Vedolizumab, but not fecal microbiota transfer (FMT), after proctocolectomy in ulcerative colitis. *Int J Colorectal Dis* 2017;32(4):597-8. DOI: 10.1007/s00384-017-2761-4
17. Coletta M, Paroni M, Caprioli F. Successful Treatment With Vedolizumab in a Patient With Chronic Refractory Pouchitis and Primary Sclerosing Cholangitis. *J Crohn's Colitis* 2017;11(12):1507-8. DOI: 10.1093/ecco-jcc/jjx090
18. Mir F, Yousef MH, Partyka EK, et al. Successful treatment of chronic refractory pouchitis with vedolizumab. *Int J Colorectal Dis* 2017;32(10):1517-8. DOI: 10.1007/s00384-017-2854-0
19. Martins D, Ministro P, Silva A. Refractory Chronic Pouchitis and Autoimmune Hemolytic Anemia Successfully Treated with Vedolizumab. *GE - Port J Gastroenterol* 2018;25(6):340-1. DOI: 10.1159/000486803
20. Orfanoudaki E, Foteinogiannopoulou K, Koutroubakis IE. Use of vedolizumab in a patient with chronic and refractory pouchitis. *Ann Gastroenterol* 2018;31(3):379. DOI: 10.20524/aog.2018.0243
21. Bär F, Kühbacher T, Dietrich NA, et al. Vedolizumab in the treatment of chronic, antibiotic-dependent or refractory pouchitis. *Aliment Pharmacol Ther*

2018;47(5):581-7.

DOI:

10.1111/apt.14479

22. Philpott J, Ashburn J, Shen B. Efficacy of Vedolizumab in Patients with Antibiotic and Anti-tumor Necrosis Alpha Refractory Pouchitis. *Inflamm Bowel Dis* 2017;23(1):e5-6. DOI: 10.1097/MIB.0000000000000992

23. Singh A, Khan F, López R, et al. Sa1829 - Vedolizumab for Chronic Antibiotic Refractory Pouchitis. *Gastroenterology* 2018;154(6):S411. DOI: 10.1016/S0016-5085(18)31652-4

Accepted Article

Table 1. Studies about the efficacy of vedolizumab in chronic refractory pouchitis

Author	Year	Type of study	Age	Sex	Anti-TNF for pouchitis	Symptom improvement at week 12	Endoscopic improvement within week 24
Schmid et al. (16)	2017	Case report	54	M	No	Yes	Yes
Coletta et al. (17)	2017	Case report	33	M	Yes	Yes	Yes
Mir et al. (18)	2017	Case report	41	F	No	Yes	Yes
Bär et al. (21)	2017	Case series 20 pts.	Median: 22.5	M: 12 F: 8	Yes: 11 No: 9	13 out of 20	9 out of 14
Martins et al. (19)	2018	Case report	20	F	Yes	Yes	Yes
Orfanoudaki et al. (20)	2018	Case report	22	F	Yes	Yes	Yes
Singh et al. (23)	2018	Case series 19 pts.	Median: 26.7	M: 10 F: 9	Yes: 9 No: 10	15 out of 19	14 out of 19

F: female; IPAA: ileal pouch-anal anastomosis; M: male; pts.: patients; TNF: tumor necrosis factor; ?: missing data.

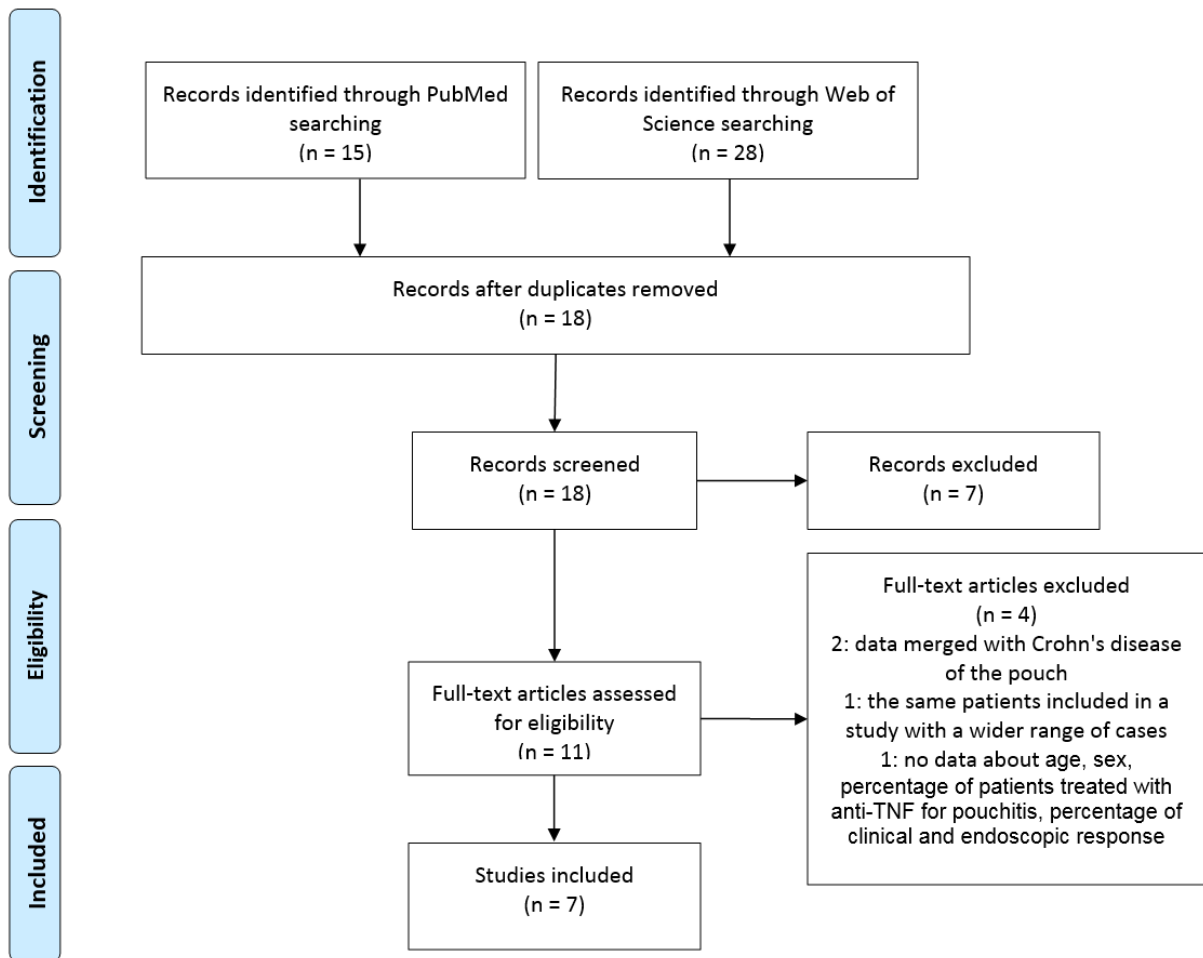


Fig. 1. Flow diagram of the study.

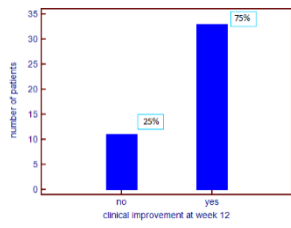


Fig. 2. Clinical improvement of pouchitis 12 weeks after vedolizumab start.

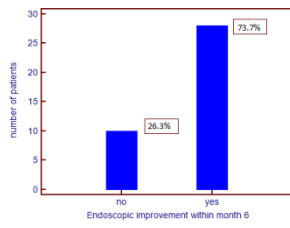


Fig. 3. Endoscopic improvement of pouchitis within 6 months after vedolizumab start.