

PICTURES IN DIGESTIVE PATHOLOGY

Combined endoscopic resolution of iatrogenic stricture in an ureterosigmoidostomy

Alberto Mir-Subías, Mónica Navarro-Dourdil, Mara Charro-Calvillo y Juan José Sebastián-Domingo

Department of Digestive Diseases. Hospital Royo Villanova. Zaragoza, Spain

INTRODUCTION

Ureteroenterostomy allows the replacement of the bladder role after radical cystectomy. Anastomotic stricture is a relatively common complication that may require surgical repair. We report a case of iatrogenic stricture in a Mainz-II ureterosigmoidostomy (1) that was satisfactorily resolved using a combined endoscopic-urological approach (2,3).

CASE REPORT

A 47-year-old male diagnosed with bladder adenocarcinoma was treated with intestinal bypass, Mainz II type. During a subsequent colonoscopy, two sessile polypoid lesions were excised, which were eventually identified as ureterosigmoidostomy-related granulomas. Follow-up revealed a ureteral dilation and anastomotic stricture in the left ureter secondary to “polypectomy”-associated scarring. Radio-guided surgery using a combined urologic-endoscopic approach was selected for treatment. A radiopaque guidewire was passed via a left nephros-

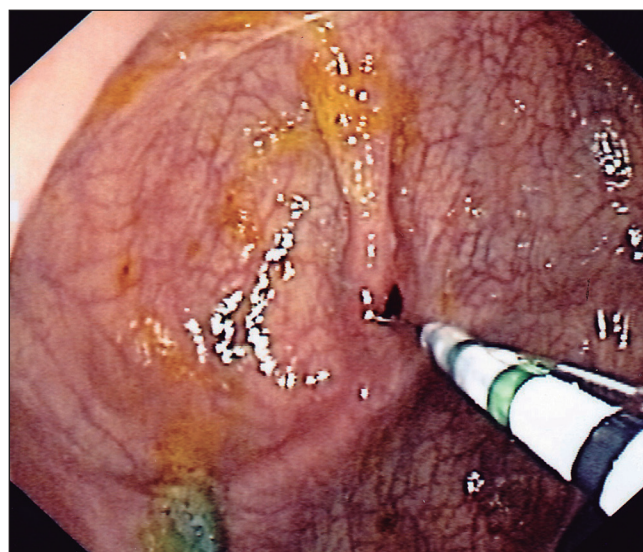

Fig. 2. Section of the strictured ureterosigmoidostomy with a conventional sphincterotome.

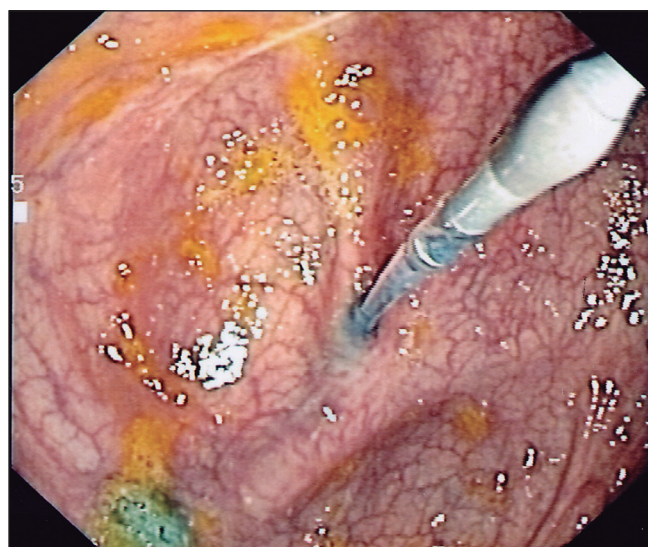

Fig. 1. Balloon dilation with a radiopaque guide wire through a left ureterosigmoidectomy stricture.

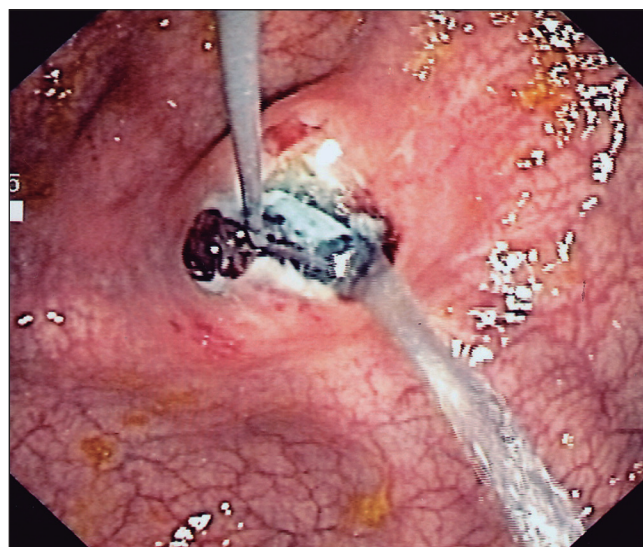


Fig. 3. Significant dilation of the ureterosigmoidostomy after section and adequate saline output through wide opened stoma.

tomy through the strictured stoma to the sigmoid colon. Endoscopically, a 6-mm-in-diameter dilation balloon was passed over the wire, which failed to significantly increase the stricture caliber. Eventually, a decision was made to widen the stricture using a conventional sphincterotome, which significantly opened the anastomosis and allowed verification of saline output. The patient had a very satisfactory outcome.

DISCUSSION

In cases of ureterosigmoidostomy-related stricture, in this case iatrogenically induced by a “polypectomy” of scarring tissue (granuloma) at the anastomosis, which

resulted in progressive fibrosis and stenosis at the stoma, repair may be attempted with a combined endoscopic technique, rendering repeated surgery unnecessary.

REFERENCES

1. Fisch M, Wammack R, Hohenfellner R. The sigma rectum pouch (Mainz pouch II). *World J Urol* 1996;14(2):68-72. DOI: 10.1007/BF00182560
2. Del Hoyo Campos J, Burgos Revilla FJ, Lovaco Castellano F, et al. Endourologic treatment of uretero-ileal stenosis. *Arch Esp Urol* 1995;48(7):735-40.
3. Kurzer E, Leveillee RJ. Endoscopic management of ureterointestinal strictures after radical cystectomy. *J Endourol* 2005;19(6):677-82. DOI: 10.1089/end.2005.19.677